

Balloon angioplasty of the A₁ segment of the anterior cerebral artery narrowed by vasospasm

Technical note

JOSEPH M. ESKRIDGE, M.D., JOON K. SONG, M.D., J. PAUL ELLIOTT, M.D.,
DAVID W. NEWELL, M.D., M. SEAN GRADY, M.D., AND H. RICHARD WINN, M.D.

Departments of Neurological Surgery and Radiology, University of Washington, Harborview Medical Center, Seattle, Washington

✓ The authors describe a new endovascular technique that improves catheterization and balloon angioplasty of the A₁ segment of the anterior cerebral artery after it has been narrowed by vasospasm. The technical results of using this method in seven patients are presented.

KEY WORDS • aneurysm • angioplasty • anterior cerebral artery • subarachnoid hemorrhage • vasospasm

SUBARACHNOID hemorrhage after aneurysm rupture often leads to cerebral vasospasm. Despite standard medical treatment with calcium channel blockers and hypertensive, hypervolemic, hemodilution therapy, up to one third of patients with vasospasm develop an ischemic neurological deficit.^{13,15,17,22} When maximum medical therapy for vasospasm fails, early and aggressive endovascular intervention with balloon angioplasty can improve clinical outcome.^{1,2,7,14,20,26} However, one disadvantage of balloon angioplasty is its limited ability to enter sharply angled vessels.

Based on our experience and confirmed by others, balloon angioplasty of the A₁ segment of the anterior cerebral artery (ACA) has been achievable in less than 10% of patients.^{2,7,14} We report a new endovascular technique that improves access to and facilitates balloon angioplasty of A₁ segments narrowed by vasospasm in selected patients. The method involves over-the-wire navigation and microguidewire support of a low-profile high-pressure balloon microcatheter system.

Endovascular Technique

The technique of performing balloon angioplasty by using the standard 4-mm low-pressure nondetachable silicone balloon microcatheter (model ITC NDSB/8502 with 0.2-ml maximum volume, 0.85-mm diameter/4.1-mm length deflated, 4.2-mm diameter/11-mm length inflated [standard ITC balloon]; Target Therapeutics/Boston Scientific, Watertown, MA) for symptomatic vasospasm has been previously described.^{10,23} If the initial diagnostic cerebral angiogram reveals normal caliber prevasospastic

A₁ segments, instead of using the standard ITC balloon, a low-profile high-pressure balloon microcatheter (Stealth Balloon Dilation System model 120502; inflated 2.5-mm diameter, 10-mm length; Target Therapeutic/Boston Scientific) is advanced across the narrowed A₁ segment with the aid of steerable hydrophilic microguidewires (Terumo 46–230, 0.016-in, 70°-angled, radiopaque gold tip tapered hydrophilic glidewire [Terumo gold tip] or Transend EX 46–801, 0.014-in, steerable microguidewire with ICE hydrophilic coating and shapeable tip [Transend EX]; Target Therapeutics/Boston Scientific) (Fig. 1).

With the assistance of biplane digital fluoroscopy and roadmapping, attempts are initially made to cross the narrowed A₁ segment with the Terumo gold tip. If successful, the microguidewire is carefully advanced to the distal pericallosal or callosomarginal artery (Fig. 2). Once the microcatheter is positioned across the A₁ segment with the aid of real-time fluoroscopic monitoring, the Stealth balloon microcatheter is dilated several times. The balloon is inflated with contrast agent that is injected using a Luer-Loc syringe attached to the Stealth balloon microcatheter via a rotating hemostatic valve.

If attempts to cross A₁-segment vasospasm with the Terumo gold tip are unsuccessful, the Transend EX can be advanced through the Stealth balloon microcatheter after shaping a tight 3- to 4-mm curve at its tip. This aids navigation of the acute bend of the terminal internal carotid artery (ICA) and the A₁ junction. Once the A₁ segment is crossed, the Transend EX is exchanged for the stiffer Terumo gold tip, which is carefully advanced to position its tip in the distal ACA. If the initial tight curve is not helpful in navigating across the A₁ segment, other curves can

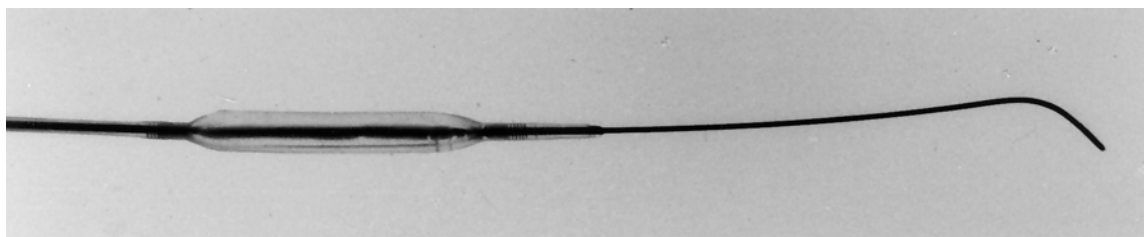


FIG. 1. Photograph showing the Stealth balloon microcatheter and steerable hydrophilic microguidewire system. The Stealth Balloon Dilatation System model 120502 (inflated 2.5-mm diameter, 10-mm length) is pictured with a Terumo 46-230, 0.016-in, 70°-angled, radiopaque gold tip, tapered hydrophilic microguidewire (Terumo gold tip).

be shaped at the tip of the Transend EX and the process can be repeated.

We have used this technique with good results in treating 10 A₁ segments narrowed by vasospasm in seven patients (Table 1).

Discussion

For patients who survive the initial event of aneurysmal

rupture, after the aneurysm has been excluded by surgical clipping or endovascular coil placement, vasospasm remains the most important cause of treatable disability.¹⁷ Various strategies to prevent or treat vasospasm and its ischemic sequelae are under investigation, including intracisternal thrombolytic therapy, a course of 21-aminosteroids (tirilazad), intraarterial papaverine infusion, and balloon angioplasty.^{16,25} Balloon angioplasty performed shortly after symptom onset appears to improve short-term and long-term clinical outcomes in patients suffering

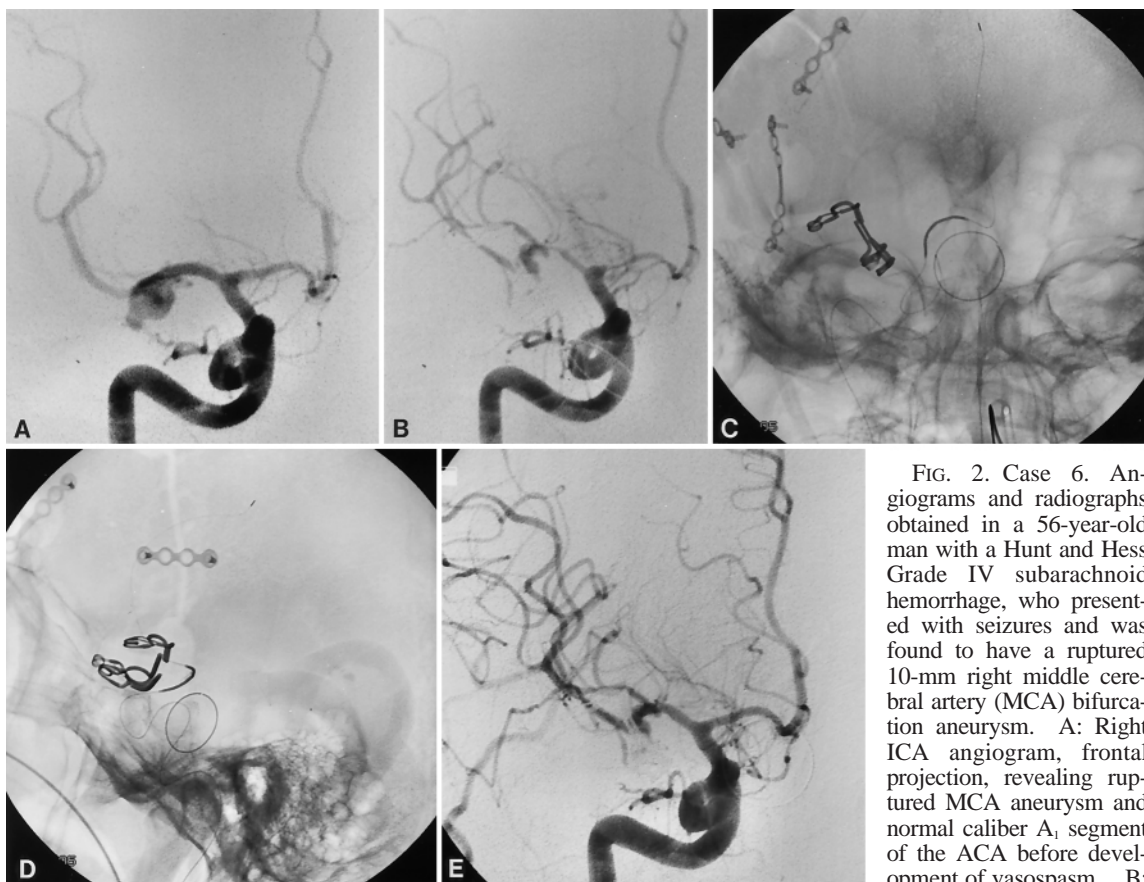


FIG. 2. Case 6. Angiograms and radiographs obtained in a 56-year-old man with a Hunt and Hess Grade IV subarachnoid hemorrhage, who presented with seizures and was found to have a ruptured 10-mm right middle cerebral artery (MCA) bifurcation aneurysm. A: Right ICA angiogram, frontal projection, revealing ruptured MCA aneurysm and normal caliber A₁ segment of the ACA before development of vasospasm. B:

After surgical clipping of the aneurysm, the patient developed vasospasm with involvement of the M₁ segment of the MCA and A₁ segment of the ACA. C and D: Frontal and lateral projection radiographs demonstrating the Stealth balloon catheter positioned and inflated across the narrowed A₁ segment with the Terumo gold tip positioned in the distal pericallosal artery. E: Following balloon inflation, repeated right ICA angiogram, frontal projection, revealing normal caliber A₁ and M₁ segments. The Stealth balloon catheter was also used to dilate the M₁ segment mechanically by using a similar technique after A₁ segment balloon angioplasty.

Balloon angioplasty of the A₁ segment of the ACA

from symptomatic vasospasm^{1,2,7,14,20,26} Moreover, the dilation produced by balloon angioplasty appears durable, with rare vasospasm recurrence. With growing experience, enthusiasm for balloon angioplasty has increased as more neurosurgeons now use this treatment modality for symptomatic vasospasm.^{4-12,18,19,21,23,24}

The importance of A₁ segment vasospasm as a contributor to incidences of morbidity and mortality related to vasospasm is underappreciated. The endovascular treatment of ACA vasospasm has been challenging. One disadvantage of balloon angioplasty is its limited ability to reach sharply angled vessels such as the A₁ segment. Balloon angioplasty of the A₁ segment is desirable because vasospasm in this location is common. Moreover, especially when the contralateral A₁ is hypoplastic or absent, A₁ segment vasospasm can lead to significant neurological deficits, including hemiparesis, hemihyesthesia, behavioral disturbances, transcortical motor aphasia, and mental deficits.³

In our experience of treating more than 150 patients with balloon angioplasty for symptomatic vasospasm during the past decade, we have found that the standard 4-mm nondetachable low-pressure ITC silicone balloon can be used to dilate the A₁ segment in less than 10% of patients. The Stealth balloon microcatheter/steerable hydrophilic microguidewire technique, however, has considerably improved our ability to access and perform balloon angioplasty on vasospastic A₁ segments.

The Stealth is stiffer than the standard ITC balloon and is, therefore, more difficult to advance through the numerous genua of the ICA. Moreover, because it is a higher-pressure balloon, the use of the Stealth carries a higher risk of vessel rupture. However, our technique modification of inflating the Stealth over a hydrophilic microguidewire addresses both of these disadvantages. In contrast to the occlusive wire supplied with the Stealth, the hydrophilic microguidewire is nonocclusive because it has no ball to close the valve. Therefore, inflations are "leaky," thereby limiting the high pressure applied by the balloon to the vessel, which probably decreases the risk of vessel rupture. Moreover, because the microguidewires are steerable and hydrophilic, they can be advanced quite distally into the ACA. Advancing the Stealth over a hydrophilic microguidewire improves balloon navigation across a stenotic A₁ segment. The distally positioned microguidewire also provides support for the balloon across the acute bend of the A₁ segment during balloon inflation. Hand-inflation pressures for the Stealth balloon are typically higher (2-3 atm) than those used for the ITC (0.5 atm). In *in vitro* experiments performed using this modified Stealth system, hand-inflation pressures greater than 25 atm have been achieved without balloon rupture while maintaining balloon shape and caliber. Therefore, the risk of balloon rupture by using this technique appears to be low. However, overly aggressive dilation can potentially rupture the vessel segment or cause occlusive dissection. We have observed one case of transient occlusive balloon microcatheter-induced spasm following A₁ segment angioplasty in a woman who was a long-time user of tobacco (Case 7).

The Stealth balloon microcatheter/steerable hydrophilic microguidewire system can also be used to perform balloon angioplasty in the M₂ and P₁ segments in selected

TABLE 1

*Technical results of A₁ segment balloon angioplasty performed using the Stealth balloon microcatheter/steerable hydrophilic microguidewire system**

Case No.	Age (yrs), Sex	Aneurysm Location	A ₁ Vasospasm		
			Before Angioplasty	After Angioplasty	Complications
1	34, M	ACoA	lt severe	none	none
2	39, F	basilar tip	lt mild rt moderate	none mild	VA dissection†
3	12, M	ACoA	lt severe rt severe	mild none	none
4	33, F	lt MCA & PA	lt severe	moderate	increased ICP preangioplasty‡
5	50, F	basilar tip	lt moderate rt severe	none moderate	none
6	56, M	rt MCA	rt severe	none	none
7	37, F	ACoA & lt SCA	rt severe	mild	rt A ₁ & M ₂ microcatheter spasm§

* ACoA = anterior communicating artery; ICP = intracranial pressure; PA = pericallosal artery; SCA = superior cerebellar artery; VA = vertebral artery.

† Not directly related to A₁ segment balloon angioplasty.

‡ Stealth balloon positioned across left A₁ segment when ICP abruptly increased. Balloon never inflated. Emergency head computerized tomography scanning revealed no new hemorrhage or infarction. Patient was treated with intraarterial papaverine infusion.

§ Immediately postangioplasty cerebral angiogram revealed occlusion of the right A₁ segment. A 24-hour follow-up cerebral angiogram revealed almost normal caliber of the A₁ (see Fig. 3).

patients. When planning multiple-vessel-segment balloon angioplasty by using the Stealth balloon microcatheter/steerable hydrophilic microguidewire system, A₁ segment balloon angioplasty should be attempted first because, once the Stealth is inflated, it never completely returns to its baseline low profile. This endovascular technique can also be used to perform balloon angioplasty in cases of intracranial atherosclerotic stenoses. On the horizon are new microguidewire-directed low-pressure silicone balloon microcatheters that should be capable of reaching the A₁ segment. Theoretically, these newer angioplasty balloon catheters should be safer and more maneuverable.

Conclusions

Vasospasm of the A₁ segment is common and can lead to significant morbidity. When balloon angioplasty for symptomatic vasospasm is pursued, all stenotic proximal vessel segments should be mechanically dilated, including narrowed A₁ segments, if technically achievable. We have found that the low-profile high-pressure Stealth balloon microcatheter/steerable hydrophilic microguidewire over-the-wire technique improves access to and balloon angioplasty in vasospastic A₁ segments. Use of the high-pressure Stealth balloon carries a higher risk of vessel rupture compared with the use of the standard low-pressure ITC balloon. Balloon angioplasty in a vasospastic A₁ segment should not be performed if the prevasospasm caliber of the A₁ segment is not known, hypoplastic, or atretic.

Disclosure

Doctor Eskridge has consulted intermittently with Target Therapeutics/Boston Scientific.

Acknowledgment

We thank Brian Bofto of Target Therapeutics/Boston Scientific for generously providing the Stealth balloon microcatheter and Terumo hydrophilic microguidewire photographed in Fig. 1.

References

1. Barnwell SL, Higashida RT, Halbach VV, et al: Transluminal angioplasty of intracerebral vessels for cerebral arterial spasm: reversal of neurological deficits after delayed treatment. **Neurosurgery** 25:424-429, 1989
2. Bejjani GK, Bank WO, Olan WJ, et al: The efficacy and safety of angioplasty for cerebral vasospasm after subarachnoid hemorrhage. **Neurosurgery** 42:979-987, 1998
3. Bogousslavsky J, Regli F: Anterior cerebral artery territory infarction in the Lausanne stroke registry: clinical and etiologic patterns. **Arch Neurol** 47:144-150, 1990
4. Bracard S, Ducrocq X, Picard L, et al: Angioplastie transluminale dans le traitement du vasospasme. Intérêt du Doppler transcrânien dans le diagnostic et le suivi. **Neurochirurgie** 38:165-169, 1992
5. Clouston JE, Numaguchi Y, Zoarski GH, et al: Intraarterial papaverine infusion for cerebral vasospasm after subarachnoid hemorrhage. **AJNR** 16:27-38, 1995
6. Clyde BL, Firlik AD, Kaufmann AM, et al: Paradoxical aggravation of vasospasm with papaverine infusion following aneurysmal subarachnoid hemorrhage. Case report. **J Neurosurg** 84:690-695, 1996
7. Coyne TJ, Montanera WJ, Macdonald RL, et al: Percutaneous transluminal angioplasty for cerebral vasospasm after subarachnoid hemorrhage. **Can J Surg** 37:391-396, 1994
8. Dion JE, Duckwiler GR, Viñuela F, et al: Pre-operative microangioplasty of refractory vasospasm secondary to subarachnoid hemorrhage. **Neuroradiology** 32:232-236, 1990
9. Elliott JP, Newell DW, Lam DJ, et al: Comparison of balloon angioplasty and papaverine infusion for the treatment of vasospasm following aneurysmal subarachnoid hemorrhage. **J Neurosurg** 88:277-284, 1998
10. Eskridge JM, McAuliffe W, Song JK, et al: Balloon angioplasty for the treatment of vasospasm: results of first 50 cases. **Neurosurgery** 42:510-517, 1998
11. Eskridge JM, Newell DW, Pendleton GA: Transluminal angioplasty for treatment of vasospasm. **Neurosurg Clin North Am** 1:387-399, 1990
12. Eskridge JM, Newell DW, Winn HR: Endovascular treatment of vasospasm. **Neurosurg Clin North Am** 5:437-447, 1994
13. Eskridge JM, Song JK: A practical approach to the treatment of vasospasm. **AJNR** 18:1653-1660, 1997
14. Firlik AD, Kaufmann AM, Jungreis CA, et al: Effect of transluminal angioplasty on cerebral blood flow in the management of symptomatic vasospasm following aneurysmal subarachnoid hemorrhage. **J Neurosurg** 86:830-839, 1997
15. Fujii Y, Takahashi A, Ezura M, et al: Balloon angioplasty immediately after surgical clipping for symptomatic vasospasm on admission. Report of four cases. **Neurosurg Rev** 18:79-84, 1995
16. Hendrix LE, Dion JE, Jensen ME, et al: Papaverine-induced mydriasis. **AJNR** 15:716-718, 1994
17. Heros RC, Zervas NT, Varsos V: Cerebral vasospasm after subarachnoid hemorrhage: an update. **Ann Neurol** 14:599-608, 1983
18. Konishi Y, Maemura E, Sato E, et al: A therapy against vasospasm after subarachnoid haemorrhage: clinical experience of balloon angioplasty. **Neurol Res** 12:103-105, 1990
19. Le Roux PD, Newell DW, Eskridge J, et al: Severe symptomatic vasospasm: the role of immediate postoperative angioplasty. **J Neurosurg** 80:224-229, 1994
20. Newell DW, Eskridge J, Mayberg M, et al: Endovascular treatment of intracranial aneurysms and cerebral vasospasm. **Clin Neurosurg** 39:348-360, 1992
21. Newell DW, Eskridge JM, Mayberg MR, et al: Angioplasty for the treatment of symptomatic vasospasm following subarachnoid hemorrhage. **J Neurosurg** 71:654-660, 1989
22. Ropper AH, Zervas NT: Outcome 1 year after SAH from cerebral aneurysm. Management morbidity, mortality, and functional status in 112 consecutive good-risk patients. **J Neurosurg** 60:909-915, 1984
23. Song JK, Elliott JP, Eskridge JM: Neuroradiologic diagnosis and treatment of vasospasm. **Neuroimaging Clin North Am** 7:819-835, 1997
24. Yamamoto Y, Smith RR, Bernanke DH: Mechanism of action of balloon angioplasty in cerebral vasospasm. **Neurosurgery** 30:1-6, 1992
25. Zabramski JM, Hamilton MG: Cerebral vasospasm, in Carter LP, Spetzler RF (eds): **Neurovascular Surgery**. New York: McGraw-Hill, 1994, pp 583-602
26. Zubkov YN, Nikiforov BM, Shustin VA: Balloon catheter technique for dilatation of constricted cerebral arteries after aneurysmal SAH. **Acta Neurochir** 70:65-79, 1984

Manuscript received October 22, 1998.

Accepted in final form February 25, 1999.

Address reprint requests to: Joseph M. Eskridge, M.D., Department of Neurological Surgery, Box 356470, University of Washington, Seattle, Washington 98195. email: jesk@u.washington.edu.