

CLINICAL NEUROSURGERY

Proceedings

OF THE
CONGRESS OF NEUROLOGICAL
SURGEONS

Orlando, Florida

1991



WILLIAMS & WILKINS
BALTIMORE • HONG KONG • LONDON • MUNICH
PHILADELPHIA • SYDNEY • TOKYO

Copyright © 1992

THE CONGRESS OF NEUROLOGICAL SURGEONS



All rights reserved. This book is protected by copyright. No part of this book may be reproduced in any form or by any means, including photocopying, or utilized by any information storage and retrieval system without written permission from the copyright owner.

Printed in the United States of America

Library of Congress
Catalog Card Number
S4-12666
ISBN 0-683-02034-X

The Publishers have made every effort to secure permission for printing identifying photographs. If they have inadvertently overlooked any, they will be pleased to make the necessary arrangements at the earliest opportunity.

The Library of Congress cataloged this serial as follows:

Congress of Neurological Surgeons.

Clinical neurosurgery. v. 1-1953-
Baltimore. Williams & Wilkins.
v. ill. 24 cm.

Annual.

"Proceedings of the Congress of Neurological Surgeons."

Issues for 1954-70 include the Membership roster of the Congress of Neurological Surgeons.

Each vol. honors an individual scientist and presents a biographical sketch, bibliography, and some of his original papers.

Indexes:

Vols. 1-19, 1953-72, in v. 19

ISSN 0069-4827 — Clinical neurosurgery.

1. Nervous system.—Surgery. I. Congress of Neurological Surgeons. Proceedings. II. Congress of Neurological Surgeons. Membership roster. III. Title.

[DNLM: W1 CL732]

RD593.A1C63 617.48

54-1266

MARC-S

92 93 94 95 96
10 9 8 7 6 5 4 3 2 1

Endovascular Treatment of Intracranial Aneurysms and Cerebral Vasospasm

DAVID W NEWELL, M.D., JOSEPH ESKRIDGE, M.D.,
MARC MAYBERG, M.D., M. SEAN GRADY, M.D., DAVID LEWIS, M.D.,
AND H. RICHARD WINN, M.D.

Endovascular therapy has emerged as a useful adjunct in treating patients with cerebrovascular disease and has stimulated the growth of a new group of subspecialists, interventional neuroradiologists. The continued advancement of this field has led to improvements in techniques and materials used to treat or used as adjuncts in treatment of aneurysms, arteriovenous malformations (AVMs), fistulas, tumors, stenotic lesions, and cerebral vasospasm from subarachnoid hemorrhage (SAH) (8). This review focuses on the treatment of *aneurysms* and *vasospasm* using endovascular techniques.

TREATMENT OF ANEURYSMS

Endovascular treatment of aneurysms began with the introduction of detachable balloons by Serbinenko (29). Since then, improvements in catheters, imaging systems, balloon materials and techniques, and more recently, the introduction of detachable coils have led to more widespread use of this technology in treating complex aneurysms. As more experience is gained with these techniques, continued assessment of the results defines their capabilities and limitations.

Treatment Options and Indications

The main options currently available for treatment of aneurysms using endovascular techniques include parent vessel occlusion, with or without trapping, and direct aneurysm occlusion using detachable balloons (2, 4, 9, 10, 13, 14, 16, 17, 28). More recently, the technique of electrothrombosis using a detachable coil introduced into the aneurysm with an endovascular approach has become available (6, 11, 12). Generally, the indications for treatment using endovascular techniques have been a failed attempt at clipping, surgical inaccessibility, or high risk of surgery because of poor underlying medical condition (14). Aneurysms

treated have included those that present with SAH and those that present with mass effect, carotid cavernous fistula, and ischemic symptoms (16). It has been recommended by some groups that patients being considered for direct balloon occlusion with recent SAH should undergo a waiting period for the thrombus in the aneurysm to organize, to avoid the complications of immediate aneurysm rupture or balloon migration (14).

General Technique

For detachable balloon therapy, initial results were obtained using carotid puncture, but more recently most groups have used the transfemoral approach. Heparinization is given routinely for the procedure. If parent vessel occlusion is being considered, a balloon test occlusion usually is performed with neurological monitoring, and, in some centers, blood flow studies are performed during test occlusion (22). Fluoroscopic guidance of catheters using a road map of the catheterized vessel is the usual procedure. After balloon positioning within the aneurysm or within the parent vessel to be occluded, 2-hydroxyethylmethacrylate (HEMA) is placed in the balloon and allowed to polymerize, followed by detachment of the catheter from the balloon.

Endovascular electrothrombosis uses a soft, detachable platinum coil that is placed in the aneurysm by an approach similar to that with detachable balloon therapy (11,12). A positive electric current then is applied through the guidewire, which then initiates thrombosis within the aneurysm by attracting negatively charged blood elements to the coil. The catheter is then detached by electrolysis of the wire that connects the catheter and the coil.

Results of Endovascular Therapy of Aneurysms

The results of endovascular therapy on aneurysms are becoming available from many different groups that use these techniques. Many patients treated have been in high-risk categories—they were not candidates for surgery because of the complexity of the aneurysms or poor health condition. In Table 20.1, results are summarized of several large series of patients treated with endovascular techniques. Follow-up studies are important in confirming the sustained effect of the treatment, and the significance of remnants or residual portions of the aneurysm neck following treatment have been emphasized (7). Figure 20.1 represents a case from our institution that shows an excellent result with complete direct occlusion using a detachable balloon. Figure 20.2 shows another case from our institution in which incomplete aneurysm occlusion was achieved, resulting in refilling of the aneurysm on a

TABLE 20.1
Results of Endovascular Occlusion of Aneurysms

Series	No. of Patients	Results	Complications Poor Results
Fox, <i>et al.</i> (9) Parent vessel occlusion	68	Permanent occlusion in 96%	13.8% morbidity 1.5% permanent morbidity
Higashida, <i>et al.</i> (17) Parent vessel occlusion	127	91% successful occlusion	5.5% morbidity 3.9% mortality
Aymard, <i>et al.</i> (2) Vertebral artery occlusion	21	62% complete occlusion	4.8% morbidity 4.8% mortality
Romodanov, <i>et al.</i> (28) Direct occlusion	119	78.2% direct aneurysm occlusion 2.5% recurrence after incomplete occlusion	2.5% stroke/death 22.7% transient deficits
Higashida, <i>et al.</i> (16) Direct occlusion	84	Direct occlusion 77.4% complete occlusion 22.6% subtotal occlusion—high incidence of aneurysm regrowth	17.9% mortality 10.7% morbidity
George, <i>et al.</i> (10) Direct occlusion and parent vessel occlusion	92	48% direct aneurysm occlusion 43% good results	36% failure of therapy death poor results
Guglielmi, <i>et al.</i> (12) Detachable coil therapy	15	93% parent vessel preservation 100% direct aneurysm occlusion 13.3% complete occlusion	6.6% transient

subsequent follow-up angiogram. Surgery was then performed to remove the balloon and clip the aneurysm. Higashida *et al.* (16) have noted a significant recurrence rate of aneurysms in patients with subtotal occlusion resulting from detachable balloons. The long-term follow-up results of detachable coil therapy have not been fully examined, but this will be important in establishing its utility.

Complications

Complications associated with endovascular therapy have included immediate or delayed rupture of the aneurysm, refilling of the aneurysm after subtotal occlusion with recurrence of symptoms or SAH, stroke related to intolerance to vessel occlusion or delayed embolic events, and balloon rupture or migration (14, 17, 18, 28). Another potential complication of a management strategy of acute SAH using detachable balloon therapy is exposure of the patient to the risk of rebleeding or vasospasm, which may not be treated as aggressively during the waiting period for definitive therapy. This may not apply to detachable coil therapy, which has been used shortly after SAH (12).

Conclusions

Endovascular therapy, including parent vessel occlusion, trapping, or direct occlusion using detachable balloons, has been used success-



FIG. 20.1. A. Illustration of an internal carotid artery aneurysm partially within the cavernous sinus before direct balloon occlusion (*arrow*). B. Illustration of the same patient 6 weeks following direct balloon occlusion of the aneurysm with successful complete obliteration (*arrow*). C. Follow-up angiogram 18 months following direct balloon occlusion showing continued complete obliteration of the aneurysm (*arrow*).

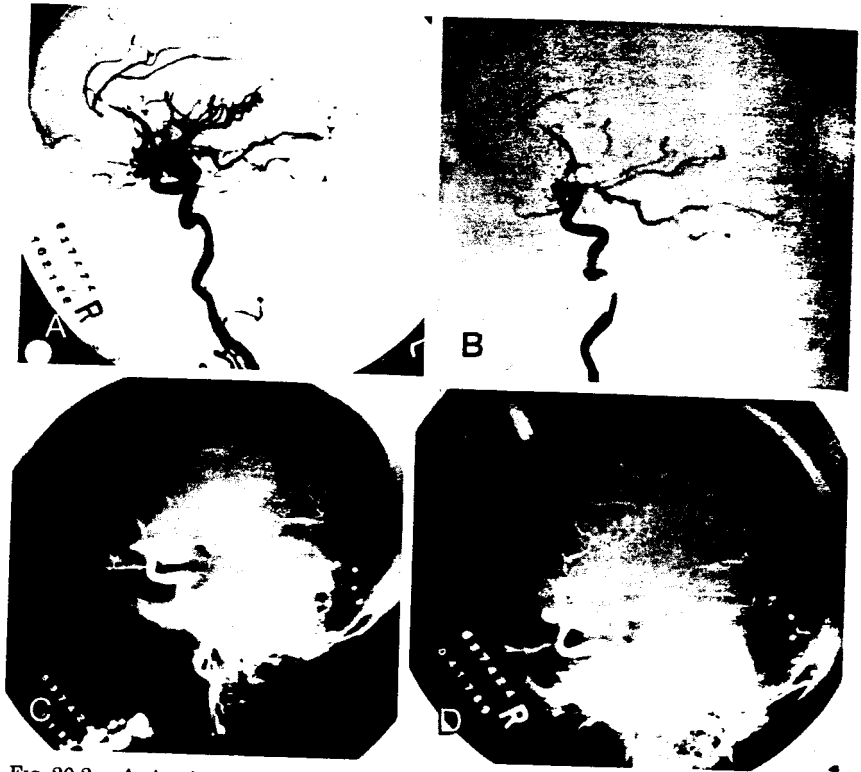


FIG. 20.2. A. Angiogram of a giant internal carotid artery aneurysm before treatment using direct balloon occlusion. B. Angiogram illustrating subtotal occlusion of the aneurysm using direct balloon occlusion. C. Follow-up angiogram illustrating reformation of the aneurysm. D. Angiogram illustrating the result of surgery that involved resection of the aneurysm and balloon and clipping of the aneurysm.

fully to treat intracranial aneurysms. More recently, electrothrombosis using detachable coils has been used. If tolerance to temporary vessel occlusion is demonstrated, then parent vessel occlusion or aneurysm trapping using this technique can yield excellent results with complex aneurysms. For obvious reasons, this technique is not applicable to aneurysms in all locations. Excellent results also have been obtained with direct balloon occlusion of aneurysms when complete obliteration is possible. A high incidence of recurrence or persistence of aneurysms has been observed with subtotal occlusion using detachable balloons. Electrothrombosis using detachable coils is a new technique for direct aneurysm occlusion. Initial results of therapy are promising, but long-term follow-up is needed. Surgical clipping remains the procedure of choice in patients in whom this is possible. Advances in surgical tech-

niques have permitted successful direct clipping of difficult aneurysms (1, 5, 30, 31). Endovascular treatment of aneurysms remains a useful strategy in the overall management of patients who have intracranial aneurysms. The decision concerning which treatment to use with complex aneurysms is best reached by analysis of each case by neurosurgeons and interventional neuroradiologists.

TREATMENT OF VASOSPASM

Endovascular treatment of vasospasm using balloon angioplasty was first introduced by Zubkov in Russia and the first series of patients was reported on in 1984 (33). The procedure uses a microballoon catheter that is navigated under fluoroscopic guidance into arteries affected by vasospasm. The microballoon then is used to dilate the arteries mechanically, thus restoring normal vessel caliber. Encouraging initial results have led to more widespread use of the technique to treat cerebral vasospasm caused by SAH (3, 15, 19, 24, 25, 32).

Indications for Angioplasty

The main indications for therapy have been the presence of vasospasm induced by SAH that was thought to be responsible for delayed ischemic neurological deficits (DINDs) in vessels accessible by microballoon catheter (basal cerebral vessels). A small number of patients also have been treated with asymptomatic vasospasm, as well as vasospasm induced by endovascular therapy for aneurysms.

GENERAL TECHNIQUE OF ANGIOPLASTY

Angioplasty is performed using several types of catheters that are custom made for this purpose. Polyethylene microballoon (Target Therapeutics Corporation, San Jose, California) and a silicone microballoon (Interventional Therapeutics Corporation, South San Francisco, California) have been used. The procedure is performed either under general anesthesia or with sedation. High-resolution fluoroscopy with road mapping capabilities is used to guide the catheter. Heparinization is performed with reversal at the conclusion of the procedure. Angiography is repeated at the end of the procedure to confirm vessel dilations.

Current Series

METHODS AND PATIENTS

The general methods for angioplasty were used in the current series. Transcranial Doppler (TCD) examinations were performed on certain

patients before and after angioplasty, and all these examinations were performed using the Medasonics Transpect (Mountain View, California) or an EME T-264B (Überingen, Germany). Patients were reexamined at regular intervals (usually daily or every other day) following the procedure for 1 week.

Ten patients had single photon emission computerized tomography (SPECT) scans performed immediately preceding and then 12 to 36 hours following the angioplasty procedure to evaluate regional cerebral perfusion. Scanning was performed after intravenous administration of 25 to 35 mCi of TC-99m hexamethyl propyleneamine oxine (HMPAO) or 1.5 mCi of I¹²³ idoamphetamine (spectamine). Tomographic acquisition was performed using a 400-AT gamma camera (General Electric, Milwaukee, Wisconsin) linked to a microdelta computer.

Between July 8, 1988 and October 8, 1991, forty-one patients at the University of Washington Affiliated Hospitals have been treated with transluminal angioplasty for vasospasm following SAH. Thirty-nine patients had SAH from ruptured intracranial aneurysms, and, in one patient, no source of bleeding was found. One patient sustained a minor head injury with significant SAH and later developed symptomatic vasospasm. The usual management protocol for the patients with SAH included early surgery for ruptured aneurysm regardless of the grade (within 72 hours of rupture), when referral permitted. All patients underwent four-vessel angiography before surgery and postoperative angiography to confirm clip replacement. Patients were monitored in the intensive care unit (ICU) using arterial blood pressure monitoring, intracranial pressure monitoring, and cardiac output monitoring (Swan Ganz catheters). Patients were treated with hypervolemia and during the later part of the series, also with calcium-channel blockers. Baseline TCD examinations were performed on most patients, except for some patients referred from other institutions for angioplasty. The TCD examinations were repeated at regular intervals, usually daily, to follow the vasospasm. Severe vasospasm was considered if mean velocity in the middle cerebral artery was ≥ 200 centimeters per second (26), or the velocity of the middle cerebral artery divided by the velocity of the extracranial carotid artery V_{mca}/V_{ica} was ≥ 6 (21). Patients generally were selected for angioplasty if they had a new onset of a neurological deficit (including decreased level of consciousness) in the presence of severe vasospasm despite maximum treatment. Other causes of deterioration were ruled out (hydrocephalus, edema, intracerebral hemorrhage) by CT scan. Angiograms were performed on all patients who were candidates for angioplasty to confirm vasospasm.




FIG. 20.3. A. Angiogram illustrating severe bilateral distal internal carotid and middle cerebral artery vasospasm in a patient after traumatic subarachnoid hemorrhage. B. Angiogram following angioplasty of distal internal carotid and middle cerebral arteries showing marked improvement in vessel caliber as well as improvement in circulation. C. SPECT scan before (*top*) and after (*bottom*) angioplasty in the same patient illustrating a regional perfusion deficit with subsequent improvement (*arrows*) the day following angioplasty. D. Serial transcranial Doppler velocity values in the same patient before and after angioplasty illustrating severe vasospasm immediately before angioplasty and subsequent resolution with persistent decreased velocity following the procedure. Velocity values are expressed as the velocity of the middle cerebral artery divided by the velocity of the extracranial internal carotid artery (V_{mca}/V_{ica}) to correct for flow changes. (See Reference 21.)

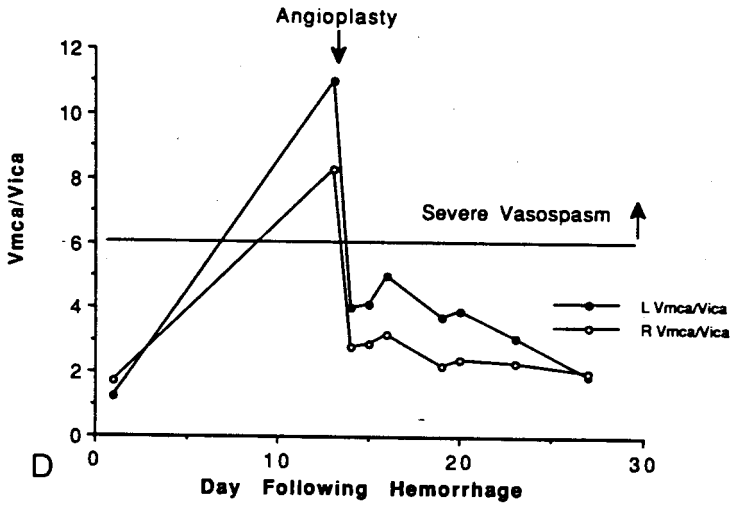
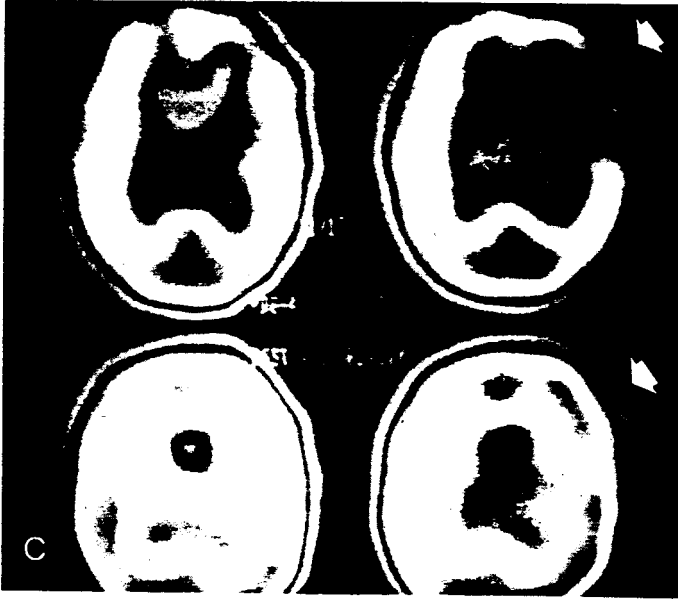

FIG. 20.3. (Continued)

RESULTS

Twenty-eight of the 39 patients who underwent this procedure for DIND had clinical improvement. Two patients underwent prophylactic angioplasty for severe vasospasm. Improvement was defined as increase of the Glasgow Coma Score by 2 points or significant improvement in speech or motor deficit. Seven deaths occurred: Two were from rupture of unclipped aneurysms and one from vessel rupture; three patients died after failing to improve from poor grades after successful angioplasty and one patient died from progressive vasospasm in an inaccessible region related to previous carotid occlusion. Twenty-nine patients had TCD examinations before and after angioplasty. Velocity values in the main portions or the dilated vessels were decreased following the procedure and were maintained below preangioplasty levels during follow-up examinations in all patients except two. On numerous occasions, vessels other than those treated developed increasing velocities, indicating progressive vasospasm during the follow-up period despite the fact that velocities in the angioplasty-treated vessels remained low. In certain patients, significantly higher velocities were observed in more distal portions of the treated artery than were present before the procedure, indicating improved flow to these distal segments.

The SPECT scan performed before and after treatment in 10 patients showed improvement of regional cerebral perfusion in eight of the patients studied. Of the two patients without improved perfusion, one had sustained intracranial circulatory arrest caused by vessel rupture and one already had sustained an infarction. Figure 20.3 illustrates angiographic, TCD, and regional cerebral perfusion studies before and after angioplasty in a patient with vasospasm.

Compiled Results of Angioplasty for Vasospasm

The results from initial reports using angioplasty for vasospasm are summarized in Table 20.2. These results illustrate that an excellent success rate can be achieved in reversing angiographic vasospasm. It also has been documented using transcranial Doppler (TCD) that the effect of the angioplasty is sustained (3, 25). Results of cerebral blood flow (CBF) studies have documented improved CBF following the procedure (20, 27). Overall, a high success rate of reversing clinical deficits has been achieved. Many failures to reverse DINDs have been in patients in whom the deficit was present for a prolonged period or cerebral infarction took place before angioplasty was accomplished.

TABLE 20.2
Results of Balloon Angioplasty for Vasospasm

Series	No. of Patients	Results		
		Angiographic	Clinical	Complications
Zubkov, <i>et al.</i> (33)	33	Improvement in all cases	? favorable	None reported directly from procedure; 21 deaths
Higashida, <i>et al.</i> (15)	13	Improvement in all cases	(9/13) 69% improved	1 hemorrhagic infarction
Newell, <i>et al.</i> (25)	10	Improvement in all cases	(8/10) 80% improved	1 branch occlusion 2 rebleeds (unclipped aneurysms)
Nemoto, <i>et al.</i> (24)	10	Improvement in 70%	(4/10) 40% improved	None
Konishi, <i>et al.</i> (19)	4	—	(4/4) 100% improved	None
Bracard (3)	5	Improvement in 100%	(5/5) 100% improved	1 vessel rupture
Takahashi, <i>et al.</i> (32)	22	Improvement in 100%	(14/20) 70% improved**	1 rebleed
Current Series	41	Improvement in 100%	(28/39) 72% improved**	1 branch occlusion 1 vessel rupture. 2 rebleeds
Total	128		(64/91) 70% improved	

* Separate from case series reported.

** Patients without DINDs.

Complications

Complications of angioplasty for vasospasm have included vessel rupture (23), vessel occlusion (25), hemorrhagic infarction in the vascular territory distal to the angioplasty (15), and rebleeding of unclipped aneurysms (25).

Conclusions

Vasospasm continues to be a significant cause of morbidity and mortality in patients with SAH. Although recent advances have been made in medical therapy for vasospasm, the problem has not been eliminated. Until better pharmacological treatments are available, angioplasty is a viable therapeutic option in patients who have been refractory to current medical therapy. It has been demonstrated that angioplasty is effective in reversing vessel narrowing and that the effect is sustained. It has also been well documented that angioplasty improves CBF in patients with vasospasm. The direct complications of the procedure, which include vessel rupture and occlusion, have not been numerous and may be minimized with further experience. Rebleeding from unclipped aneurysms represents a serious complication and we now recommend that every effort be made to clip the aneurysm before attempting angioplasty. The clinical success of the procedure depends on

selecting patients for treatment early after onset of DIND; maximum benefit is obtained in patients who have not sustained cerebral infarction. The early identification of DINDs remains problematic, especially in poor-grade patients.

REFERENCES

1. Archer, D. J., Young, S., and Uttley, D. Basilar aneurysms: a new transclival approach via maxillotomy. *J. Neurosurg.* 67: 54-58, 1987.
2. Aymard, A., Gobin, Y. P., Hodes, J. E., *et al.* Endovascular occlusion of vertebral arteries in the treatment of unclippable vertebrobasilar aneurysms. *J. Neurosurg.* 74: 393-398, 1991.
3. Bracard, S., Picard, L., Ducrocq, JCMX., *et al.* Role of angioplasty in treatment of symptomatic vascular spasm occurring in the post-operative course of intracranial ruptured aneurysms. *J. Neuroradiol.* 17: 6-19, 1990.
4. Debrun, G., Fox, A., Drake, C., *et al.* Giant unclippable aneurysms: Treatment with detachable balloons. *AJNR* 2: 167-173, 1981.
5. Dolenc, V. Direct microsurgical repair of intracavernous vascular lesions. *J. Neurosurg.* 58: 824-831, 1983.
6. Dowd, C. F., Halbach, V. V., Higashida, R. T., *et al.* Endovascular coil embolization of unusual posterior inferior cerebellar artery aneurysms. *Neurosurgery* 27: 954-961, 1990.
7. Drake, C. G., and Vanderlinden, R. G. The late consequences of incomplete surgical treatment of cerebral aneurysms. *J. Neurosurg.* 27: 226-238, 1967.
8. Eskridge, J. M. Interventional neuroradiology. *Radiology* 172: 991-1006.
9. Fox, A. J., Vinuela, F., Pelz, D. M., *et al.* Use of detachable balloons for proximal artery occlusion in the treatment of unclippable cerebral aneurysms. *J. Neurosurg.* 66: 40-46, 1987.
10. George, B., Aymard, A., Merland, J. J., *et al.* Efficiency of balloon treatment of intracranial aneurysms. In: *Intracranial Aneurysms and Arteriovenous Malformations*, edited by K. Sugita and M. Shibuya, pp. 347-351. Nagoya University Coop Press, Nagoya, 1990.
11. Guglielmi, G., Vinuela, F., Sepetka, I., and Macellari, V. Electrothrombosis of saccular aneurysms via endovascular approach. Part 1: Electrochemical basis, technique, and experimental results. *J. Neurosurg.* 75: 1-7, 1991.
12. Guglielmi, G., Vinuela, F., Dion, J., and Duckwiler, G. Electrothrombosis of saccular aneurysms via endovascular approach. Part 2: Preliminary clinical experience. *J. Neurosurg.* 75: 8-14, 1991.
13. Hieshima, G. B., Higashida, R. T., Wapenski, J., *et al.* Balloon embolization of a large distal basilar artery aneurysm. *J. Neurosurg.* 65: 413-416, 1986.
14. Hieshima, G. B., Higashida, R. T., and Halbach, V. V. Intravascular treatment of aneurysms. *Clin. Neurosurg.* 36: 338-343, 1988.
15. Higashida, R. T., Halbach, V. V., Cahan, L. D., *et al.* Transluminal angioplasty for treatment of intracranial arterial vasospasm. *J. Neurosurg.* 71: 648-653, 1989.
16. Higashida, R. T., Halbach, V. V., Barnwell, S. L., *et al.* Treatment of intracranial aneurysms with preservation of the parent vessel: Results of percutaneous balloon embolization in 84 patients. *AJNR* 11: 633-640, 1990.
17. Higashida, R. T., Halbach, V. V., Dowd, C. F., *et al.* Intracranial aneurysms: interventional neurovascular treatment with detachable balloons—results in 215 cases. *Radiology* 178: 663-670, 1991.

18. Hodes, J. E., Fox, A. J., Pelz, D. M., and Peerless, S. J. Rupture of aneurysms following balloon embolization. *J. Neurosurg.* 72: 567-571, 1990.
19. Konishi, Y., Tokitsu, M., Sato, E., *et al.* Percutaneous transluminal angioplasty (PTA) for vasospasm after subarachnoid hemorrhage. In: *Cerebral Vasospasm*, edited by K. Sano, K. Takakura, N. F. Kassell, and T. Sasaki. pp. 440-442. University of Tokyo Press, Tokyo, 1990.
20. Lewis, D. H., Eskridge, J., Newell, D., and Winn, H. R. SPECT of regional brain blood flow before and after cerebral angioplasty. *J. Nucl. Med.* 32: 971a, 1991.
21. Lindegaard, K. F., Nornes, H., Bakke, S. J., *et al.* Cerebral vasospasm diagnosis by means of angiography and blood velocity measurements. *Acta Neurochir. (Wien)* 100: 12-24, 1989.
22. Linskey, M. E., Sekhar, L. N., Horton, J. A., *et al.* Aneurysms of the intracavernous carotid artery: a multidisciplinary approach to treatment. *J. Neurosurg.* 75: 525-534, 1991.
23. Linskey, M. E., Horton, J. A., Rao, G. R., and Yonas, H. Fatal rupture of the intracranial carotid artery during transluminal angioplasty for vasospasm induced by subarachnoid hemorrhage. *J. Neurosurg.* 74: 985-990, 1991.
24. Nemoto, S., Abe, T., Tanaka, H., *et al.* In: *Cerebral Vasospasm*, edited by K. Sano, K. Takakura, N. F. Kassell, and T. Sasaki. pp. 437-439. University of Tokyo Press, Tokyo, 1990.
25. Newell, D. W., Eskridge, J. M., Mayberg, M. R., *et al.* Angioplasty for the treatment of symptomatic vasospasm following subarachnoid hemorrhage. *J. Neurosurg.* 71: 654-660, 1989.
26. Newell, D. W. Evaluation of vasospasm using transcranial Doppler. In: *Cerebral Vasospasm*, edited by K. Sano, K. Takakura, N. F. Kassell, and T. Sasaki. pp. 3-8. University of Tokyo Press, Tokyo, 1990.
27. Pistoia, F., Horton, J. A., Sekhar, L., and Horowitz, M. Imaging of blood flow changes following angioplasty for treatment of vasospasm. *AJNR* 12: 446-448, 1991.
28. Romodanov, A. P., and Shcheglov, V. I. Intravascular occlusion of saccular aneurysms of the cerebral arteries by means of detachable balloon catheter. In: *Advances and Technical Standards in Neurosurgery*, vol 9, edited by H. Krayenbuhl. pp. 25-49. Springer-Verlag Wien, New York, 1982.
29. Serbinenko, F. A. Balloon catheterization and occlusion of major cerebral vessels. *J. Neurosurg.* 41: 125-145, 1974.
30. Spetzler, R. F., Hadley, Mark N., Rigamonti, D., *et al.* Aneurysms of the basilar artery treated with circulatory arrest, hypothermia, and barbiturate cerebral protection. *J. Neurosurg.* 68: 868-879, 1988.
31. Sundt, T. M., Jr., Piepgras, D. G., Marsh, W. R., *et al.* Bypass vein grafts for giant aneurysms and severe intracranial occlusive disease in the anterior and posterior circulation. In: *Occlusive Cerebrovascular Disease, Diagnosis and Surgical Management*, edited by T. Sundt, Jr., pp. 439-464. W. B. Saunders, Philadelphia, 1991.
32. Takahashi, A., Yoshimoto, T., Mizoi, K., *et al.* Transluminal balloon angioplasty for vasospasm after subarachnoid hemorrhage. In: *Cerebral Vasospasm*, edited by K. Sano, K. Takakura, N. F. Kassell, and T. Sasaki. pp. 429-432. University of Tokyo Press, Tokyo, 1990.
33. Zubkov, Y. N., Nikiforov, B. M., and Shustin, V. A. Balloon catheter technique for dilatation of constricted cerebral arteries after aneurysmal SAH. *Acta Neurochir.* 70: 65-79, 1984.