

## Dynamic Transcranial Doppler Assessment of Positional Vertebrobasilar Ischemia

Matthias Sturzenegger, MD; David W. Newell, MD; Colleen Douville, BA, RVT;  
Sheila Byrd, RVT; Ketti Schoonover, BS, RVT

**Background and Purpose** A hemodynamic as opposed to an embolic origin of vertebrobasilar ischemia may be suspected when symptoms are brief and triggered by changes in the position of the head or neck. It may be difficult, and not without risk, to reproduce the symptoms and to prove the short-lived hemodynamic changes during angiography. If transcranial Doppler sonography (TCD) could detect these changes, it would be useful as a noninvasive screening method to select patients for further diagnostic evaluation.

**Methods** TCD monitoring of the P1 segments of both posterior cerebral arteries was performed during different head movements in 14 patients referred for evaluation of suspected hemodynamic vertebrobasilar ischemia and in 10 healthy control subjects with a two-channel, 2-MHz, computerized Doppler system. Patients' symptoms were correlated with the Doppler findings.

**Results** Four patients with stereotypical symptoms had a severe drop in posterior cerebral artery blood flow velocities (BFVs) to 20% of baseline (mean; SD, 14.3; range, 0% to 48%) and subsequent reactive hyperemia with an increase in BFV to 149% (mean; SD, 20.6; range, 110% to 186%) dependent on head rotation to one side (group 1). Compared with the values found in group 2 patients and in control subjects, these drops were significant ( $P=.0001$  for both). Symptoms together with BFV changes could be reproduced several times. Angiography confirmed severe vertebral artery

obstruction during head rotation and the presence of anomalies in the posterior circulation. In 10 patients (group 2), symptoms were not short-lived, stereotyped, or clearly dependent on head movements and could not be reproduced during TCD testing. Their BFVs dropped to 88% (mean; SD, 9.0; range, 64% to 102%) of baseline values during maximal head rotation, to 86% (mean; SD, 10.3; range, 64% to 100%) during flexion, and to 88% (mean; SD, 6.7; range, 75% to 103%) during extension. In the 10 control subjects, BFVs dropped to 86% (mean; SD, 8.8; range, 61% to 98%) of baseline values during rotation, to 90% (mean; SD, 10.3; range, 74% to 107%) during flexion, and to 76% (mean; SD, 17.1; range, 54% to 104%) during extension.

**Conclusions** Monitoring posterior cerebral artery BFV during head movements is a simple, noninvasive method to document a hemodynamic etiology of symptoms in patients with suspected positional vertebrobasilar ischemia. The correlation of symptoms to the hemodynamic findings proved a useful screening method to identify those patients with true position-evoked hemodynamic insufficiency in the posterior circulation. These patients should be selected for angiographic evaluation to identify the source and site of arterial compression. (*Stroke*. 1994;25:1776-1783.)

**Key Words** • Doppler • hemodynamics • ultrasonics • vertebrobasilar circulation

Transient symptoms of ischemia in the vertebrobasilar territory may be due to artery-to-artery embolism or to hemodynamic insufficiency.<sup>1,2</sup> However, there are no data on the percentage of the contribution of these two origins. Positional vertebrobasilar ischemia can occur and may cause well-defined clinical symptoms. The most common cause of this clinical entity is positional obstruction of one or both vertebral arteries (VAs). It is important to accurately diagnose this syndrome because it can respond very well to surgical decompression. The anatomic course of the VAs in the osseous canal formed by the transverse foramina predisposes them to impingement from vertebral spondylarthrosis in the cervical segment, particularly during head rotation.<sup>3-5</sup> This is compensated for by the unique condition of two VAs joining to supply the intracranial vascular bed. Unilateral, com-

plete VA obstruction may occur in healthy people during head rotation or extension without symptoms<sup>6-8</sup> because the contralateral VA may provide compensation by increasing its flow. Additional collateral pathways include the posterior communicating arteries (PcomAs), which may compensate immediately for bilateral cessation of VA flow, and extensive collateral anastomoses with cervical arteries originating from the extracranial carotid artery and the subclavian artery. However, the latter require a certain amount of time to become hemodynamically effective.

Anomalies of the VA are not rare: hypoplasia of one VA is found in 10% to 20%, depending on its definition.<sup>3,4,9</sup> The second most frequent anomaly is termination of one VA in the posterior inferior cerebellar artery (PICA) without blood supply to the basilar artery. One VA may also be obstructed as a result of unilateral atherosclerosis, shifting the main blood supply of the brain stem, cerebellum, and temporo-occipital brain areas to the contralateral VA. If the PcomAs are anatomically normal and supplied from the carotids, even temporary occlusion of such a dominant VA would not be expected to cause ischemic symptoms. However, it is well known that anomalies in the posterior part of the circle of Willis are also common: 48% to 79% of

Received April 4, 1994; final revision received June 16, 1994; accepted June 16, 1994.

From the Department of Neurological Surgery, University of Washington, Seattle.

Correspondence to M. Sturzenegger, MD, Department of Neurology, University of Bern, Inselspital, CH-3010 Bern, Switzerland.

© 1994 American Heart Association, Inc.

analyzed circles of Willis at autopsy showed hypoplasia of one or more component stems, the higher rates associated with brains showing softening.<sup>10,11</sup> The most frequent finding is a hypoplastic PcomA in 17% to 59% (depending on the associated brain pathology), which is bilateral in 20% to 27%, followed by a fetal origin of the posterior cerebral artery (PCA) in 15% to 29% (main supply from the carotid artery with a hypoplastic P1 PCA segment), which is bilateral in 5%.<sup>10-12</sup> With respect to vertebrobasilar compensatory blood supply, the PcomA is of particular relevance. The combination of a VA anomaly or disease and a PcomA anomaly seems necessary to cause vertebrobasilar ischemia provoked by head movements.

Symptoms of vertebrobasilar ischemia are frequently nonspecific, consisting of attacks of dizziness, vertigo, lightheadedness, and visual disturbances.<sup>13,14</sup> More specific symptoms such as dysarthria, ataxia, unilateral or bilateral sensory disturbances of face or extremities, double vision, crossed sensory or motor symptoms, bilateral leg weakness, or drop attacks are much rarer.<sup>13-16</sup> It can be difficult based on clinical symptoms alone to determine if symptoms provoked by head rotation are due to positional hemodynamic insufficiency or due to other causes. It would be valuable to

have a method to positively establish whether symptoms have a hemodynamic cause. Angiography can then be used to identify the cause of hemodynamic insufficiency.

Doppler examination may be an effective noninvasive method to screen such patients for selection for further angiographic studies. Transcranial Doppler sonography (TCD) allows continuous monitoring of blood flow velocities (BFVs) in the PCAs during different maneuvers, such as head rotation. We evaluated 14 patients with suspected positional hemodynamic vertebrobasilar ischemia and 10 healthy control subjects using this technique.

## Subjects and Methods

### Patients

During a 2-year period 14 patients were referred to our cerebrovascular laboratory with suspected hemodynamic vertebrobasilar ischemia based on symptoms of dizziness, vertigo, or visual troubles during head rotation, triggered by certain positions or postures (6 men, 8 women; mean age, 57 years [range, 34 to 76 years]). The patients were interviewed concerning their symptoms and precipitating factors. Special emphasis was placed on the exact analysis of triggering movements or positions, as well as those bringing symptomatic relief, and on the duration of the symptoms (Tables 1 and 2).

TABLE 1. Clinical and Radiological Findings in Patients With Extrinsic Vertebral Artery Compression

Pt	Age, y/Sex	History	Symptoms	Cervical Spine X-ray	Angiography
1	37/F	Recurrent neck injury; degenerative cervical spine disease; MS (intermittent vertigo, sensory disturbances)	Only induced by head turning to right, spells lasting seconds: dizziness, vertigo, tinnitus, dimmed vision, bilateral leg weakness, hemiparesis, numbness	Multilevel degenerative disc disease	Small deviation of right VA in neutral head position; severe obstruction of right VA at C5/C6 level and of left VA at C1/C2 level on head rotation to right; no PcomAs imaged
2	52/M	Degenerative cervical spine disease; neck pain	Only induced by head turning to right, while driving, spells lasting seconds: lightheadedness, dizziness, vertigo, blurred vision, bilateral leg weakness and numbness, rarely passing out	Osteophytes and uncovertebral hypertrophy at all levels	Hypoplastic left VA, terminating in PICA; dominant right VA without obstruction in neutral position but severe obstruction at C3/C4 level on head rotation to right; no PcomAs imaged
3	78/F	Recurrent neck injury; odontoid fracture; severe neck pain; degenerative cervical spine disease	Only induced by head turning to left, spells lasting seconds: bilateral leg weakness, tingling in legs or all four extremities, loss of equilibrium, headache	Chronic nonunion of type 2 odontoid fracture; extensive degenerative disc disease of lower cervical spine	Severe extrinsic compression of dominant right VA and minimal of left VA in neutral position at the level of C2; both right and left VAs are almost occluded with left lateral oblique head position; no PcomAs imaged
4	71/M	Degenerative cervical spine disease; neck pain	Only induced by head turning to right, spells lasting seconds: dizziness, vertigo, blurred vision	Osteophytes and uncovertebral hypertrophy at all levels	Absent (occluded?) left VA; small right VA; multilevel severe extrinsic compression of right VA on head rotation to right; 50% stenosis of right ICA; no PcomAs imaged

Pt indicates patient; MS, multiple sclerosis; VA, vertebral artery; PcomA, posterior communicating artery; PICA, posterior inferior cerebellar artery; and ICA, internal carotid artery.

## Methods

All patients had conventional extracranial Doppler examination and TCD. Then, by means of a two-channel, 2-MHz Doppler system (Multi-Dop X/TCD 7, Firma DWL, Elektronische Systeme GmbH), the TCD transducers were fixed to the temporal bone with a specially designed headband for long-term monitoring, and both PCAs were insonated. The PCAs were identified from the transtemporal approach according to standard criteria such as anatomic landmarks (insonation angle, depth of sample volume, and spatial relation of the Doppler spectra to those of the middle cerebral artery, anterior cerebral artery, and the bifurcation of the internal carotid artery), direction of flow, and compression and oscillation maneuvers of the common carotid artery and the VA.<sup>17</sup> The transmission of oscillatory pressure waves to both recorded PCA signals was required during rapid suboccipital oscillations of either VA (Fig 1). Also required was a clear-cut BFV increase while measuring visually evoked flow during eye opening as opposed to eye closing (with the special system software allowing BFV averaging) in both PCAs<sup>18</sup> (Fig 2). While the BFVs in both PCAs (P1 segment) were simulta-

neously monitored continuously on-line, patients were instructed to slowly and sequentially perform the following head movements: rotation to either side, maximal flexion, and maximal extension. The beginning and end of any movement were registered with a marker signal on a separate channel (Fig 3), and occurrence of any symptoms was documented. Each movement was performed at least two times. Off-line analysis of changes in the recorded mean maximal BFV in both PCAs during each head movement was performed; maximal drops were calculated as percentage of baseline values. Baseline values were calculated as the mean of the 10 cycles while the head was in a neutral position, preceding the head movements.

Cervical spine x-ray films were available for review in all patients (Tables 1 and 2). The four patients with marked drop of BFV (group 1) underwent subsequent angiography (Table 1). Two of the 10 patients without a major drop of BFV (group 2) already had angiography before TCD examination (Table 2, patients 6 and 7).

## Control Subjects

Ten healthy volunteers without any history of transient symptoms suggestive of vertebrobasilar ischemia or orthostasis

**TABLE 2. Clinical Findings in Patients Without Extrinsic Vertebral Artery Compression**

Pt	Age, y/Sex	History	Symptoms	Comment
1	34/F	Degenerative cervical disc disease; 3 whiplash injuries; neck pain for 3 years; panic attacks	Daily episodes of visual blurring, rarely blackouts; when rising, bending, on any head movement	"Cervicogenic" dysfunctions
2	66/M	Two vertebrobasilar strokes, probably embolic	Episodic lightheadedness, loss of balance, nausea; duration hours to days; not dependent on head movement	VBI on clinical grounds; probably embolic
3	50/F	Arnold-Chiari malformation type 1 with syrinx C2; cervical spine disease after MVA	Episodes of blurred vision and poor equilibrium, numbness and weakness of legs; duration up to hours; rarely induced by head movement	VBI on clinical grounds; mechanical VA compression due to herniated tonsils?
4	50/M	Peripheral arterial occlusive disease; persistent tinnitus and dizziness for 1 year, hearing loss	Episodes of dizziness at night when turning in bed, not dependent on head movement alone; duration seconds to minutes	Most probably cochleovestibular disease
5	54/F	Degenerative cervical disc disease	Dimming of vision when turning head to left	
6	73/M	Known left VA occlusion; right ICA stenosis (95%); status post-left ICA CEA	Dizziness when turning head to right or on rolling over in bed	VBI on clinical grounds; probably embolic
7	54/M	Left VA occlusion; right VA stenosis (70%), V3 segment; fetal origin of both PCAs, large PcomAs	Episodes of dizziness, nausea, diplopia; not dependent on head movement or position; duration seconds to minutes	VBI on clinical grounds; probably embolic
8	45/F	Severe MVA, closed head injury, skull base fractures, middle and inner ear trauma	Episodes of anxiety, panic, dizziness, reduced hearing; not dependent on head position or movement; duration days	Cochleovestibular disease; Ménière's disease possible
9	75/F	Degenerative cervical disc disease accentuated since MVA with multiple bone fractures	Positional dizziness and vertigo when lying down; not dependent on head movement; duration seconds	Benign paroxysmal positional vertigo
10	58/F	Degenerative cervical disc disease; panic attacks	Dizziness and blurred vision when looking up to ceiling, maximal when head back in neutral position; duration several minutes	

Pt indicates patient; VBI, vertebrobasilar insufficiency; MVA, motor vehicle accident; VA, vertebral artery; ICA, internal carotid artery; CEA, carotid endarterectomy; PCA, posterior cerebral artery; and PcomA, posterior communicating artery.

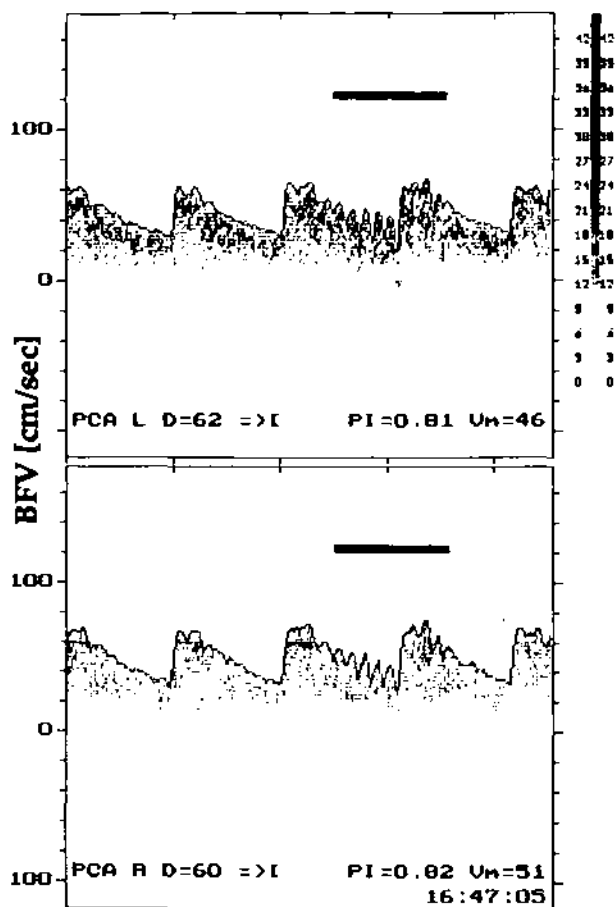


FIG 1. Posterior cerebral artery (PCA) blood flow velocity (BFV) signals recorded simultaneously in the left (L) and the right (R) P1 segments with a transtemporal approach. Repetitive short oscillations of the vertebral artery applied in the suboccipital region on the atlas loop segment (horizontal bar) evoke a positive response with transmission of the oscillatory pressure waves into the PCAs. D indicates insonation depth; PI, pulsatility index; and Vm, mean maximal velocity.

and without any known medical disease or regular medication were examined by TCD according to the same technique and protocol as described for the patients.

### Statistical Analysis

The values of decreases in BFV during the different head maneuvers in the patient groups and the control subjects were compared with the Mann-Whitney *U* test.

### Results

In four patients (group 1) we found a marked drop of PCA BFV during TCD monitoring, which was exclusively induced by head rotation to one particular side; this drop was reproducible several times and was associated with the patients' typical transient symptoms (Table 1). The extent of the drops was variable, related to various degrees of performed head rotation (mean, to 20% of baseline values; SD, 14.3; range, 0% to 48%); however, in any trial it dropped to below 50% in all four patients (Fig 4). These drops were significantly different from BFV drops during head rotation measured in patients of group 2 ( $P=.0001$ ) and in control subjects ( $P=.0001$ ). All extensive drops were followed immediately by a transient increase (reactive hyperemia) of the

BFV above baseline values on return of the head to a neutral position and symptomatic relief. The extent of the BFV increase was again variable: mean, 149% of baseline values; SD, 20.6; range, 110% to 186% (Figs 3 and 4). These findings suggested hemodynamically significant, mechanical, extrinsic VA compression, which could be confirmed on subsequent angiography.

Details of cerebral four-vessel angiography are listed in Table 1. In all patients there was an absence of PcomAs after injections of the VAs and internal carotid arteries, with the head in a neutral position. Additionally, in the two patients with unilateral extrinsic VA compression during head rotation, the opposite VA was occluded (patient 4) or hypoplastic (patient 2). The other two patients had bilateral compression during head rotation. Extrinsic VA compression during head rotation was due to degenerative cervical disc disease with uncoupled and zygoapophyseal spondylarthrotic spurs in three patients (patients 1, 2, and 4). Surgical exploration and decompression also revealed a far lateral soft discal herniation in two patients who had subtotal VA obstruction in the second segment (patients 1 and 2). The third patient refused surgical intervention. Patient 3, who had subtotal, bilateral VA obstruction at the C1/C2 level, had hypermobility of this segment because of a chronic type 2 odontoid fracture. After bilateral VA decompression and C1/C2 posterior fusion, she no longer had spells, and during TCD reexamination the maximal drop in BFV was to 90% of baseline values only. Clinical symptoms in these four patients were characterized by short duration (seconds), dependence on one specific head movement, immediate relief on return of the head to a neutral position, and stereotypical presentation. However, the latter was quite nonspecific, with dizziness (not vertigo) and blurred vision (not diplopia) most frequently reported (Table 1). Interestingly, none had symptoms triggered by rising.

Ten patients (group 2) had only small changes of BFV during provocative head maneuvers. These were not reproducible, not dependent on a specific head movement, and did not evoke their symptoms. Recorded drops for all performed movements, taking the values of both PCAs together, were to a mean of 87% of baseline values (SD, 8.8; range, 64% to 103%), without any significant difference between rotation to either side (drop to a mean of 88%; SD, 9.0; range, 64% to 102%), flexion (drop to a mean of 86%; SD, 10.3; range, 64% to 100%), or extension (drop to a mean of 88%; SD, 6.7; range, 75% to 103%) (Fig 4). Comparing the drops of BFV in group 2 with those found in the control subjects, there was a significant difference for head extension only ( $P=.02$ ) but not for flexion or rotation. The symptoms of these patients were not strictly dependent on head movements, especially not on one specific head maneuver, they were long lasting (hours to days), and they were not relieved when the head was back in a neutral position. They consisted mainly of dizziness and visual disturbances (Table 2).

In control subjects (10 healthy subjects; 4 men, 6 women; mean age, 33 years [range, 21 to 45 years]) during head movements, taking both PCAs together, for all performed head maneuvers, PCA BFV dropped to 85% of baseline values (mean; SD, 12.7; range, 54% to 107%) (Fig 4). The mean drop during head rotation

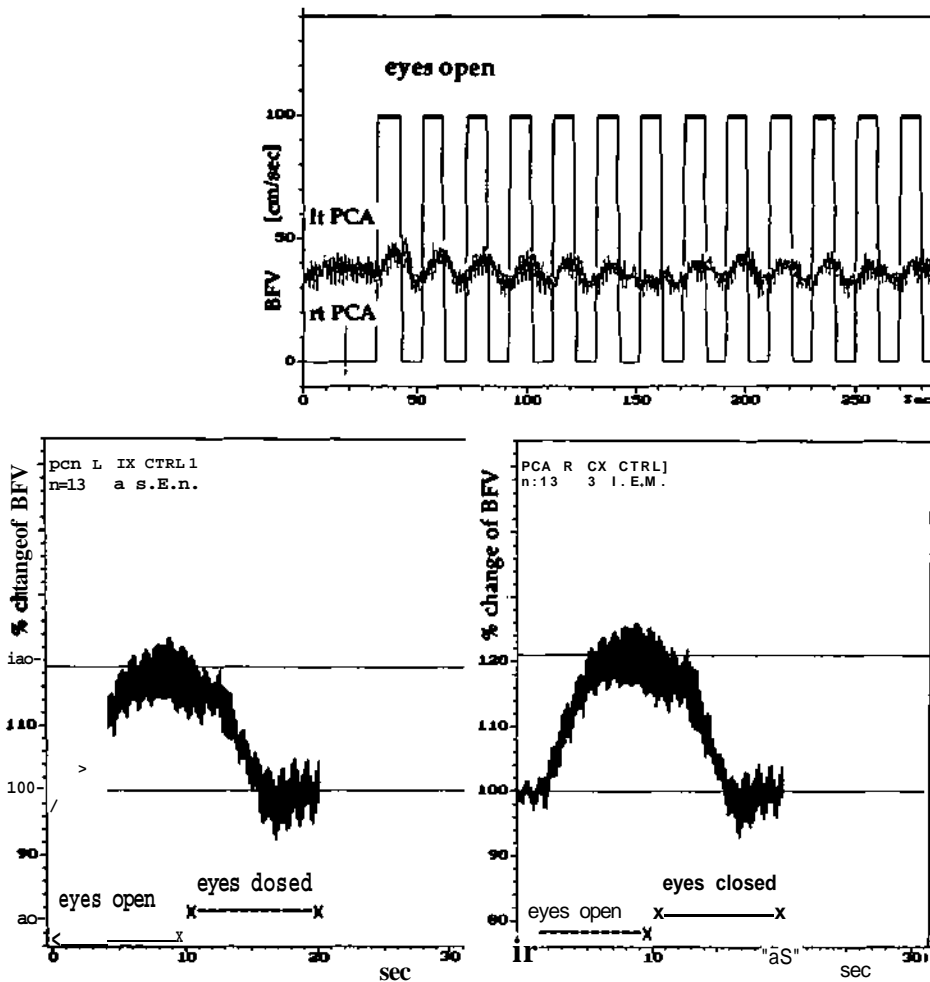


FIG 2. Visually evoked flow response recorded simultaneously in the P1 segments of left (lt) posterior cerebral artery (PCA) and right (rt) PCA. Stimulus is daylight, with eyes open as opposed to eyes closed serving as baseline. Top, Trend recording of mean maximal blood flow velocity (BFV), demonstrating a regular increase with eyes open (10 seconds, thick horizontal bars) and decrease with eyes closed (10 seconds). Bottom, Averaged velocity response in the left (L) and the right (R) PCAs during 13 cycles (n=13) (10-second stimulus on, with eyes open; 10-second stimulus off, with eyes closed) expressed as percentage of baseline values (% CTRL). Mean increase of BFV was 19% on the left side and 21% on the right side. The shaded area indicates 2 SEM.

to either side was 86% (SD, 8.8; range, 61% to 98%), during flexion 90% (SD, 10.3; range, 74% to 107%), and during extension 76% (SD, 17.1; range, 54% to 104%). The values during extension were significantly different from those during rotation ( $P=.02$ ) and during flexion ( $P \geq .01$ ).

### Discussion

As a result of excellent time resolution, continuous TCD with on-line registration allows the assessment of dynamic short-time changes in BFV.<sup>19</sup> Four of 14 patients with suspected vertebrobasilar ischemia due to intermittent external VA compression had marked drops in BFV of both PCAs during head rotation to one side (group 1). The mean drop was to 20% of baseline and was below 50% of baseline in any trial. These changes were associated with the patients' typical clinical symptoms, and both were immediately relieved when the head was turned back to a neutral position, which thus confirmed a causal relation. A second constant finding, in addition to the extent of the BFV drops, that distinguished these patients from those of group 2 and the control subjects was the regular occurrence of a transient increase of BFV (reactive hyperemia) subsequent to the drops, when the neutral head position was resumed (Fig 3). These changes of the PCA BFV together with the clinical symptoms dependent on a particular head maneuver could be reproduced several times.

The 10 remaining patients (group 2) had only minor drops in BFV induced by various head maneuvers. The mean drop was to 87% of baseline BFV and did not fall below 60% in any case. The drops were not associated with clinical symptoms, not uniformly reproducible, and not followed by reactive hyperemia. There was no difference between the drops of group 2 patients and those found in the control subjects except during head extension, which led to a significantly larger drop in the control subjects (Fig 4). Two of the control subjects showed during one of several hyperextension trials a slight reactive hyperemia not exceeding 110% of baseline values. The most likely explanation is a larger range of extension in the significantly younger control subjects and a better compliance during the maneuvers since they had no symptoms.

A detailed history could already distinguish between these two patient groups: Symptoms associated with hemodynamic vertebrobasilar ischemia were characterized by their short duration (seconds), dependence on one specific head movement, immediate relief on return of the head to the neutral position, reproducibility, and stereotypical presentation. The latter was, however, quite nonspecific, with dizziness (not vertigo) and blurred vision (not diplopia) most frequently reported.

Vertebrobasilar insufficiency is a vaguely defined syndrome, a construct of symptoms, each nonspecific.<sup>13,14,20</sup> Dizziness, by far the most common symptom, is difficult to distinguish from similar episodes that occur in many

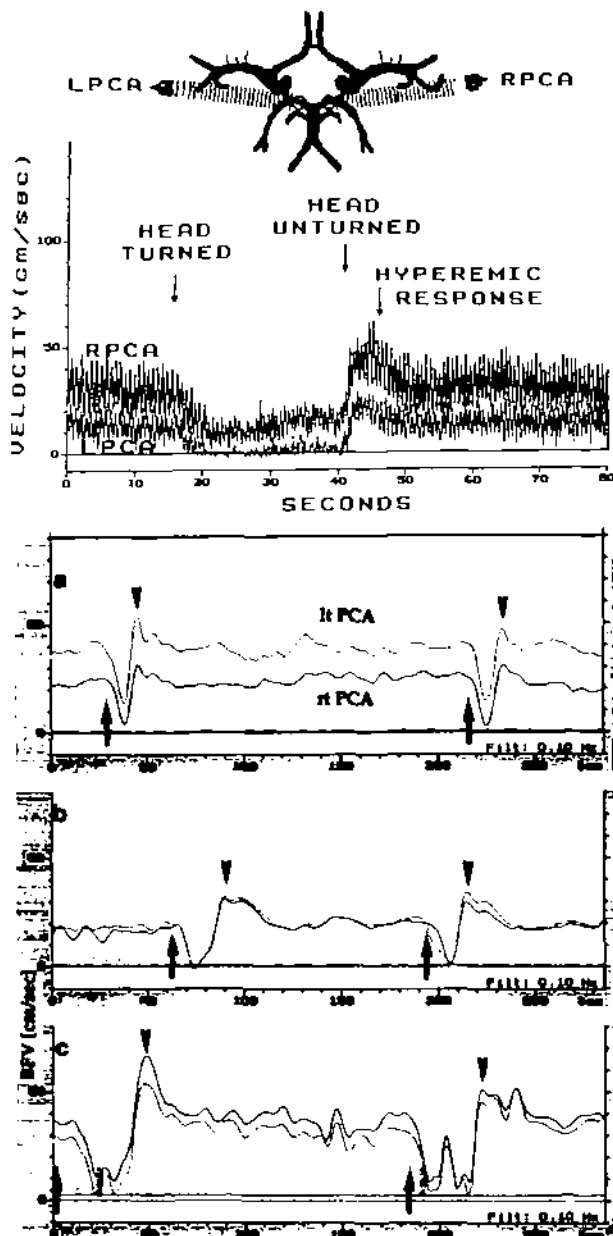


Fig 3. Upper panel, Illustration of temporal transducer position to insonate the P1 segments of the right (R) posterior cerebral artery (PCA) and left (L) PCA (top). Unfiltered blood flow velocities (BFVs) of the RPCA and LPCA of patient 4 of group 1 are shown during head rotation to the right (bottom). Lower panel, Tracings of continuously recorded BFV in the P1 segments of left (lt) and right (rt) PCAs during head movements in patients of group 1 (a, patient 1; b, patient 2; and c, patient 3). A low-pass filter (Filt) (0.10 Hz) was used to eliminate cluttering by pulsatility. There is a marked drop during head turning to the right (a and b) or to the left (c) side, with a subsequent reactive hyperemia (arrowheads) when the head is brought back to a neutral position. This response is reproducible on each trial of head rotation. The beginning of the rotation is marked by an arrow.

circulatory, neurological, epileptic, and emotional disturbances.<sup>13,16</sup> Clinical symptoms do not identify the nature and site of the original cardiovascular process. The listed characteristics of the spells, as exhibited by group 1, are very helpful hints to a distinct etiology, namely, intermittent extrinsic VA compression.<sup>13</sup> Diagnostic attempts today in the very heterogeneous entity

of vertebrobasilar occlusive disease should aim at the delineation of subdivisions.<sup>13,14,20,21</sup> This approach provides the basis for specific individually tailored treatment since anticoagulation is no longer the only option: Proximal VA stenosis may be eliminated either by surgery<sup>22</sup> or angioplasty<sup>23</sup>; distal stenosis in certain cases may be treated with endarterectomy<sup>24</sup>; and external mechanical VA compressions with other causes can be cured by various decompressive procedures.<sup>21,25,26</sup>

Intermittent, hemodynamic vertebrobasilar ischemia can be due to a systemic blood pressure drop (eg, cardiac failure or orthostasis) or to local compromise of VA blood flow. It was established decades ago in arteriographic studies performed on cadavers and also in volunteers that head rotation and extension can cause VA obstruction.<sup>6,27-30</sup>

Extrinsic mechanical compression of the VA due to pathological conditions is certainly underestimated since it occurs in most cases asymptotically.<sup>21</sup> This is due to the special anatomic characteristics of the posterior circulation that enable multiple collateral channels at several levels between the VA origin and the PCAs to preserve cerebral blood flow. One would require high-grade bilateral VA obstruction or unilateral obstruction in the presence of contralateral VA anomaly (eg, hypoplasia) or disease (stenosis, thrombosis) and inadequate collateral flow from the anterior circulation to cause hemodynamic ischemic symptoms. Preexisting, contralateral VA anomalies or disease (in cases with unilateral extrinsic compression) and functionally absent PcomAs on both sides were found in all four patients of group 1. A wide array of disorders leads to extrinsic VA compression at different levels, such as anomalous muscle insertions,<sup>8,31-33</sup> osseous malformations,<sup>34</sup> fractures or dislocations, rheumatoid arthritis,<sup>35</sup> or space-occupying lesions.<sup>21</sup> However, osteophytic spurs protruding into the transverse foramen, as in our patients, are the most frequently reported cause.<sup>21,25,36,37</sup> On the other hand, cervical disc rupture, additionally found in two of our patients, is only rarely reported,<sup>38</sup> probably because it is in most cases associated with osteophytes (protruding laterally) and usually extruded in the posterior direction, where the VA is not at risk.

Monitoring VA flow at the atlas loop via a suboccipital, lateral probe position by means of the freehand technique and the dynamic changes that occur when the patients perform various head movements<sup>39,40</sup> has proven unsatisfactory, in our opinion and that of others.<sup>17,41,42</sup> As a result of soft tissue movement during head positioning, the depth of the vessel of interest changes, and difficulties in maintaining vessel insonation as well as probe motion artifacts are encountered. Furthermore, even in the case of true cessation of flow registered in the VA, there can be no inference as to the more relevant velocity changes in the supplied end arteries, such as the PCAs, or on its relevance with respect to tissue perfusion.

The TCD monitoring technique used in this study offers several advantages. First, stable probe fixation to the temporal skull eliminates most inadvertent probe motion artifacts. Second, the end arteries of the posterior circulation are monitored; the net flow changes in these vessels are much more clinically relevant than, for example, those in the VAs proximal to the circle of Willis, and these changes result not only from the effects

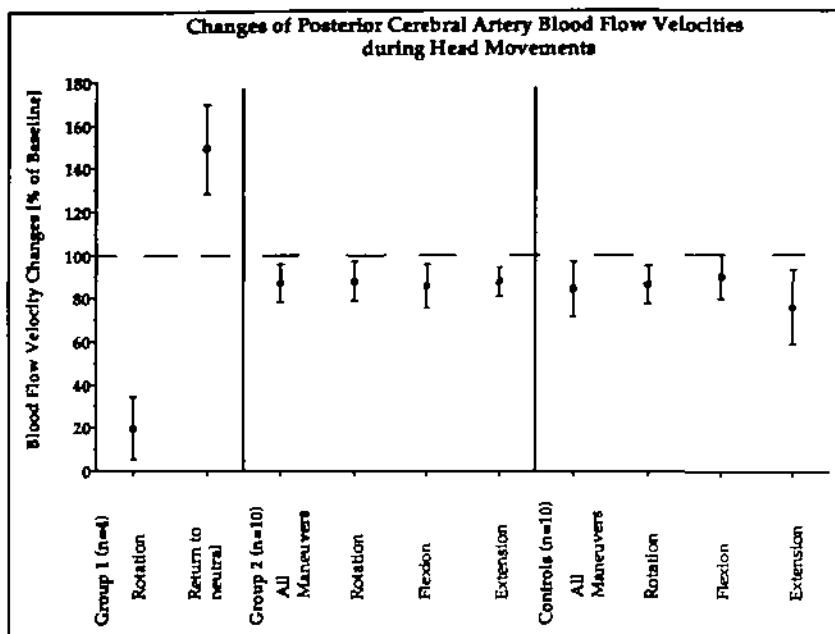


FIG 4. Graph demonstrates changes of the mean maximal blood flow velocities (BFVs) recorded in the two patient groups and control subjects during the performed head maneuvers. Responses in both posterior cerebral arteries are taken together and expressed as percent change of the baseline velocities taken at rest in the neutral head position. In group 1 patients, only the values (drops of BFV) during the head rotation that induced symptoms and the values of the subsequent reactive hyperemia when the head was turned back to a neutral position are shown. In group 2 patients and control subjects, the BFV changes during the different head maneuvers are shown (mean  $\pm$  2 SD).

of VA compromise but also from available collateral flow from the opposite VA or the circle of Willis across the PcomAs. Third, simultaneous recording of both PCAs provides duplicate security for observing significant changes, which would be expected to occur to a similar degree in both vessels. In the setting of marked PcomA asymmetry, unilateral PCA changes will not be missed. Postischemic reactive hyperemia is an important phenomenon confirming that true cessation of flow has occurred, rather than a simple loss of the Doppler signal due to motion-induced probe displacement.

The PCAs must be clearly identified to rely on this functional testing. We recommend not only the known standard landmarks described<sup>43</sup> but also compression and oscillation maneuvers of the suboccipital VAs, showing pressure wave transmission to both PCAs (Fig 1), and use of visually evoked flow (Fig 2) to identify the PCAs definitively.<sup>18</sup> We recommend monitoring the P1 segment of the PCAs, allowing for simultaneous assessment of the efficiency of the PcomAs. One would assume an absence of hemodynamically efficient PcomAs in the case of a severe drop of orthograde P1 segment BFV. Reversal of flow direction with a substantial flow signal, on the other hand, would indicate efficient PcomA collateral flow.

Limitations of this technique are (1) absence of a temporal "acoustical bone window," which may prevent insonation of basal cerebral arteries in 10% to 15% of an elderly population<sup>42</sup>; (2) inability to identify the PCA despite an adequate bone window because of anatomic variations, which may be encountered in 10% to 15%<sup>17</sup>; and (3) bilateral PCA origin from the internal carotid artery without significant contribution from the basilar system in approximately 7%.<sup>10-12</sup> The latter anatomic variation might cause difficulties in identifying the P1 segment (usually hypoplastic in this situation). Taking the P2 segment instead is likely to show visually evoked BFV responses but nevertheless cannot serve as a monitoring site to exclude hemodynamic vertebrobasilar ischemia. This situation demonstrates the impor-

tance of the oscillation maneuvers: There would be no PCA responses to VA but a clear response to common carotid artery compression.

In our experience the described TCD method is a simple, easily performed, noninvasive way to diagnose hemodynamically relevant mechanical compression of the VA. It seems a suitable method to select patients with appropriate clinical presentation for further angiographic investigation. The latter is necessary since Doppler does not provide information about the cause and the site of mechanical VA compression.

## References

- Pessin MS, Daneault N, Kwan ES, Eisengart MA, Caplan LR. Local embolism from vertebral artery occlusion. *Stroke*. 1988;19:112-115.
- Koroshetz WJ, Ropper AJ. Artery-to-artery embolism causing stroke in the posterior circulation. *Neurology*. 1987;37:292-296.
- Francke JP, di Marino V, Pannier M, Argenson C, Libersa C. The vertebral arteries (arteria vertebralis): the V3 atlanto-axial and V4 intracranial segments-collaterals. *Anat Clin*. 1981;2:229-242.
- Argenson C, Francke JP, Sylla S, Dintimille H, Papasian S, di Marino V. The vertebral arteries (segments V1 and V2). *Anat Clin*. 1980;2:29-41.
- Hutchinson EC, Yates PO. The cervical portion of the vertebral artery: a clinico-pathological study. *Brain*. 1956;79:319-331.
- Faris AA, Poser CM, Wilmore DW, Agnew CH. Radiologic visualization of neck vessels in healthy men. *Neurology*. 1963;13:386-396.
- Yang PJ, Latack JT, Gabrielsen TO, Knake JE, Gebarski SS, Chandler WF. Rotational vertebral artery occlusion at C1-C2. *AJNR Am J Neuroradiol*. 1985;6:98-100.
- Husni EA, Bell HS, Storer J. Mechanical occlusion of the vertebral artery: a new clinical concept. *JAMA*. 1966;196:475-478.
- Lang J. Craniocervical region, blood vessels. *Neuro Orthop*. 1986;2:55-69.
- Riggs HE, Rupp Ch. Variation in form of the circle of Willis. *Arch Neurol*. 1963;8:24-30.
- Alpers BJ, Berry RG. Circle of Willis in cerebral vascular disorders. *Arch Neurol*. 1963;8:68-72.
- Battacharji SK, Hutchinson EC, McCall AJ. The circle of Willis: the incidence of developmental abnormalities in normal and infarcted brains. *Brain*. 1965;15:747-758.
- Bryun GW. Vertigo and vertebrobasilar insufficiency. *Acta Otolaryngol*. 1988;460(suppl):128-134.
- Caplan LR. Vertebrobasilar disease: time for a new strategy. *Stroke*. 1981;12:111-114.

15. Rancurel G, Kieffer E, Arzimanoglu A. Vertebrobasilar ischemic disease: one or more entities? 460 cases. *Neurol Res.* 1992; 14(suppl):174-176.
16. Grad A, Baloh R. Vertigo of vascular origin. *Arch Neurol.* 1989;46: 281-284.
17. Buedingen HJ, Staudacher T. Evaluation of vertebrobasilar disease. In: Newell DW, Aaslid R, eds. *Transcranial Doppler.* New York, NY: Raven Press, Ltd; 1992:167-195.
18. Aaslid R. Visually evoked dynamic blood flow response of the human cerebral circulation. *Stroke.* 1987;18:771-775.
19. Aaslid R. Cerebral hemodynamics. In: Newell DW, Aaslid R, eds. *Transcranial Doppler.* New York, NY: Raven Press, Ltd; 1992: 49-55.
20. Ausman JI, Shrontz CE, Pearce JE, Diaz FG, Crecelius JL. Vertebrobasilar insufficiency: a review. *Arch Neurol.* 1985;42:803-808.
21. George B, Laurian C. Impairment of vertebral artery flow caused by extrinsic lesions. *Neurosurgery.* 1989;24:206-214.
22. Spetzler RF, Hadley MN, Martin NA, Hopkins LN, Carter LP, Budny J. Vertebrobasilar insufficiency, part I: microsurgical treatment of extracranial vertebrobasilar disease. *J Neurosurg.* 1987;66:648-661.
23. Higashida RT, Tsai FY, Halbach VV, Dowd FC, Smith T, Fraser K, Hieshima GB. Transluminal angioplasty for atherosclerotic disease of the vertebral and basilar arteries. *J Neurosurg.* 1993;78: 192-198.
24. Anson JA, Spetzler RF. Endarterectomy of the intradural vertebral artery via the far lateral approach. *Neurosurgery.* 1993;33: 804-811.
25. Nagashima C. Vertebral artery insufficiency and cervical spondylosis. In: Fein JM, Flam ES, eds. *Cerebrovascular Surgery.* New York, NY: Springer-Verlag New York, Inc; 1985:529-555.
26. Bakay L, Leslie EV. Surgical treatment of vertebral artery insufficiency caused by cervical spondylosis. *J Neurosurg.* 1965;23: 596-602.
27. Toole JF, Tucker SH. Influence of head position upon cerebral circulation: study of blood flow on cadavers. *Arch Neurol.* 1960;2: 616-623.
28. de Kleyn A, Nieuwenhuys P. Schwindelanfaelle und Nystagmus bei einer bestimmten Kopfstellung. *Acta Otolaryngol (Stockh).* 1927;11:155-157.
29. Tatlow WFT, Bammer HG. Syndrome of vertebral artery compression. *Neurology.* 1957;7:331-340.
30. Brown BSTJ, Tatlow WFT. Radiographic studies of the vertebral arteries in cadavers. *Radiology.* 1963;81:80-88.
31. Kojima N, Tamaki N, Fujita K, Matsumoto S. Vertebral artery occlusion and the narrowed 'scaleno-vertebral angle': mechanical vertebral occlusion in the distal first portion. *Neurosurgery.* 1985; 16:672-674.
32. Dadsetan MR, Skerhut HEI. Rotational vertebrobasilar insufficiency secondary to vertebral artery occlusion from fibrous band of the longus colli muscle. *Neurodiology.* 1990;32:514-515.
33. Hardin CA, Poser CM. Rotational obstruction of the vertebral artery due to redundancy and extraluminal cervical fascial bands. *Ann Surg.* 1963;158:133-137.
34. Menezes AH, Van Gilder JC, Graf CJ, McDonnell DE. Cranio-cervical abnormalities: a comprehensive surgical approach. *J Neurosurg.* 1980;53:444-455.
35. Jones MW, Kaufmann JCE. Vertebrobasilar artery insufficiency in rheumatoid atlantoaxial subluxation. *J Neurol Neurosurg Psychiatry.* 1976;39:122-128.
36. Shehan S, Bauer RB, Meyer JS. Vertebral artery compression in cervical spondylosis. *Neurology.* 1960;10:968-986.
37. Hardin CA. Vertebral artery insufficiency produced by cervical osteoarthritic spurs. *Arch Surg.* 1965;90:629-632.
38. Budway RJ, Senter HJ. Cervical disc rupture causing vertebrobasilar insufficiency. *Neurosurgery.* 1993;33:745-747.
39. Capasso G, Testa V, Bonoavolonta A. The Doppler stress test for the vertebral arteries. *Ital J Orthop Traumatol.* 1991;17:141-144.
40. Alexandrov AV, Norris JW. Recurrent stroke caused by spondylotic compression of the vertebral artery. *Ann Neurol.* 1994; 35:126. Letter.
41. Brautaset NJ. Provokable bilateral vertebral artery compression diagnosed with transcranial Doppler. *Stroke.* 1992;23:288-291.
42. Fujioka KA, Ernsberger AM, Nicholls SC, Spencer MP. Transcranial Doppler assessment of mechanical compression of the vertebral arteries. *J Vasc Technol.* 1991;15:254-259.
43. Fujioka KA, Douville CM. Anatomy and freehand examination techniques. In: Newell DW, Aaslid R, eds. *Transcranial Doppler.* New York, NY: Raven Press, Ltd; 1992:9-31.