Interventional Endovascular Therapy: SPECT Cerebral Blood Flow Imaging Compared With Transcranial Doppler Monitoring of Balloon Angioplasty and Intraarterial Papaverine for Cerebral Vasospasm

David H. Lewis, MD, J. Paul Elliott, MD, David W. Newell, MD, Joseph M. Eskridge, MD, and H. Richard Winn, MD

The effects of interventional endovascular treatment of cerebral vasospasm with balloon angioplasty or papaverine infusion were evaluated by single-photon emission computed tomography (SPECT) and transcranial Doppler (TCD) in 44 patients whose cerebral vasospasm was refractory to medical management. SPECT revealed blood flow improvements in 42% of patients with papaverine treated vessels and 70% of patients with balloon angioplasty ($P = .037$). TCD correlated with SPECT in 71% of patients in the papaverine group and 73% of patients in the balloon angioplasty group. TCD showed 93% of segments improved by angioplasty, whereas 43% of segments were improved with papaverine ($P < .001$). Disagreements were largely represented by patients with TCD velocity improvements in which SPECT blood flow imaging was unchanged or worsened. Balloon angioplasty seems superior to papaverine infusion for treatment of vasospasm. SPECT and TCD are complementary tests in the evaluation of vasospasm and effect of interventional therapy.
Key Words: Single photon emission—Computed tomography—Cerebral blood flow—Transcranial Doppler—Subarachnoid hemorrhage—Cerebral vasospasm.

Interventional treatment of cerebral vasospasm was first described in 1984 when Zubkov et al. used a microballoon catheter for dilatation of constricted cerebral arteries.[1] Since then, this technique has provided a successful treatment option for patients with vasospasm remaining refractory to medical management.[2] More recently, intra-arterial papaverine has been used for direct pharmacological dilatation of arteries affected by vasospasm.[3] We have previously evaluated the effect of balloon angioplasty or papaverine treatment using single-photon emission computed tomography (SPECT) to evaluate changes in cerebral blood flow.[4,5] The present study was performed to compare a group of patients who had subarachnoid hemorrhage–induced vasospasm solely treated with balloon angioplasty versus a similar group solely treated with intra-arterial papaverine via study with cerebral blood flow imaging with SPECT and vascular monitoring with transcranial Doppler (TCD).

Patients and Methods

Between February 1989 and June 1995, 44 patients with cerebral vasospasm secondary to subarachnoid hemorrhage received interventional treatment with either balloon angioplasty or intraarterial papaverine after failure of medical treatment.[6,7] These patients had symptomatic vasospasm based on neurological worsening during the period of vasospasm. There were no new findings of abnormality on noncontrast head computed tomography (CT), such as hydrocephalus, rehemorrhage, or new low-

From the Departments of Radiology and Neurological Surgery, Harborview Medical Center, University of Washington School of Medicine, Seattle, WA.
Received July 1, 1998; accepted September 24, 1998.
Address reprint requests to David H. Lewis, MD, Director, Nuclear Medicine, Associate Professor of Radiology, Harborview Medical Center, University of Washington School of Medicine, 325 Ninth Avenue, 359772, Seattle, WA 98104.

1052-3057/99/0802-0004$3.00/0

density areas, to explain the neurological decline. If hydrocephalus was present, it was treated promptly, yet neurological decline persisted despite therapy. Informed consent was obtained before treatment from patient or patient representative. After diagnostic angiography, proximal intracranial vessels showing significant angiographic vasospasm were treated with either balloon angioplasty or intraarterial papaverine. Treatment using balloon angioplasty consisted of balloon dilatation of the vasospastic segments that were the intracranial supraclinoid internal carotid arteries, and M1 and M2 segments of the middle cerebral artery (MCA).

For balloon angioplasty, a transfemoral approach was used for placement of introducer catheter in the internal carotid artery after heparinization. A low pressure silicone angioplasty balloon (Target Therapeutics Corporation, San Jose, CA) was attached to a microcatheter of variable stiffness. With high resolution digital fluoroscopy and digital road mapping, the balloon was inflated and deflated in less than 5-second intervals along the course of the vessel in spasm, moving from proximal to distal along the artery. Heparinization was reversed after intervention with protamine sulfate. Normally, the anterior cerebral arteries are not treated using balloon angioplasty due to the difficulty in placing the guide wire and balloon in the proximal anterior cerebral artery. For papaverine infusion, the microcatheter was placed proximally to the vessel in spasm. Three hundred milligrams of papaverine were infused with intracranial pressure and hemodynamic monitoring for 20 minutes to 1 hour.[8] Patients were chosen for endovascular therapy with balloon angioplasty if they had vessels that were accessable by the microballoon and for treatment with papaverine if they had vessels that were not likely to be approached by balloon as judged by the interventional neuroradiologist.

All 44 patients underwent brain scans before and after endovascular treatment using SPECT with Tc-99m HMPAO (Ceretec; Amersham, Arlington Heights, IL) and rotating gamma camera (n = 44 scans on GE 400AT; GE Medical Systems, Milwaukee, WI; n = 44 scans on Picker Prism 3000; Picker International, Cleveland, OH) for a total 88 scans. Images were produced via step and shoot acquisition at 1 hour or more after intravenous administration of 30 mCi Tc-99m HMPAO with radiopharmaceutical purity of at least 80% by thin layer chromatography. Data were reconstructed via filtered back-projection with attenuation correction via the Chang boundary method.[9] Images were added to slice thicknesses comparable to the full width at half maximum of the instrument and displayed in transverse, coronal, and sagittal planes. Scans were obtained within 24 hours before or after treatment.

SPECT was interpreted by two observers via consensus reading by visual comparison of radiopharmaceutical uptake in the supratentorial cortex to uptake in cerebellum simultaneously on both the pre- and post-interventional studies to determine the following: (0) worsened perfusion in MCA territory; (1) no change in perfusion in MCA territory; or (2) improved perfusion in MCA territory for each vascular territory treated.

Patients were scanned via TCD with Transpect TCD probe (Medasonics, Mountain View, CA). One patient had no TCD data in both vessels treated with papaverine and one had data from one of two vessels that were treated with balloon angioplasty. All others had comparable TCD velocity information from the middle cerebral arteries before and after interventional treatment. The highest velocity (cm/s) at each vessel segment was recorded before and after angioplasty or papaverine therapy within 24 hours. Mean velocity was used for diagnostic purposes. Other TCD criteria such as pulsatility were not factored in because of the possible complex effects of angioplasty or papaverine on these measurements.

Results

SPECT

In 18 patients treated with intraarterial papaverine, 24 vessels were infused with 300 mg. Twenty-two of 24 vascular beds had hypoperfusion on initial SPECT (92%). Ten of 24 had improved blood flow on follow-up SPECT (42%), 9 of 24 had no change (38%), and 4 of 16 had blood flow deterioration on the second scan (20%) (Fig 1).

Of 26 patients treated with balloon angioplasty, 37 of 43 vascular beds had hypoperfusion on the initial scan (86%, P = ns compared with papaverine group). Thirty of 43 segments had improvement of blood flow on follow-up scan (70%, $P = .037$ compared with papaverine group, Fisher Exact test), 6 of 43 had no change (14%), and 7 of 43 had worsened perfusion on the second scan (16%).

TCD

TCD data were available for all patients except 1 in the papaverine group (n = 2 vessels) and 2 patients (n = 2 vessels) in the balloon group (Table 1). Vasospasm was described as velocity increase greater than 120 cm/s. The mean velocity of the vessels before treatment was 160 cm/s. Improvement was described as change on second scan after intervention to lower velocity. No improvement was less than 10 cm/s change and worsening was change to higher velocity by more than 10 cm/s.

Of 18 patients treated with intraarterial papaverine, 9 of 21 (43%) had improvement of velocities, 4 of 21 (19%) had no change, and 8 of 21 vessel segments (38%) showed adverse velocity change.

Of 26 patients treated with balloon angioplasty, 38 of 41 vessel segments (93%) showed improvement of velocities (v papaverine, $P < .001$ Fisher Exact test), 1 of 41 showed

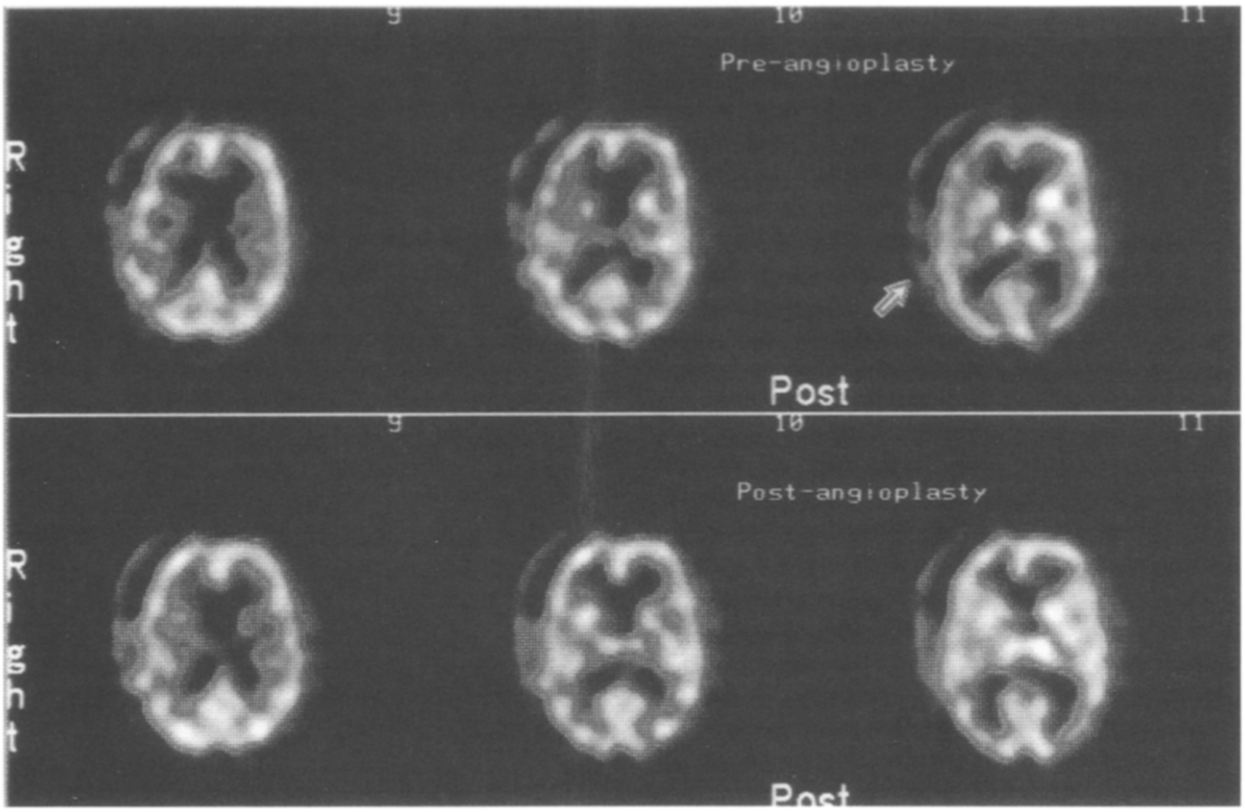

Figure 1. *Tc-99m HMPAO transverse axial SPECT images before (top) and after (bottom) treatment of right middle cerebral vasospasm by balloon angioplasty. Note hypoperfusion in right hemisphere denoted by arrow that resolves on second scan.*

no significant change (3%), and 2 of 41 were adversely changed (5%).

SPECT Versus TCD

Comparing TCD to SPECT, there was agreement in 15 of 21 vessel segments treated with papaverine (71%, $P < .1$, chi square test) with the disagreements reflecting 3 cases in which vessel velocity declined but SPECT was unchanged in 2 and worse in 1 and 3 other cases in which velocities increased but SPECT showed improvement.

Comparing TCD to SPECT, there was agreement in 30 of 41 vessel segments treated with balloon angioplasty (73%, $P < .1$, chi square test). Six vascular beds had normal SPECT before treatment, and after intervention, 4 had no change and 2 had worsening perfusion, whereas 6 vessel segments had improved velocities on TCD. The other 5 vascular beds had hypoperfusion on SPECT that was unchanged (n = 1) or worsened (n = 4) in the setting of improved velocities on TCD in 4 and worsened in 1.

Comparing the results of TCD with SPECT in each group, there was no significant difference between the rate of agreement, 71% versus 73%.

Table 1. *Results summary*

	Papaverine (%)	Balloon (%)
SPECT hypo pre-Rx vessels in spasm	92	86
Improved blood flow on SPECT	42	70*
Improved velocity on TCD	43	93†
Agreement between TCD/SPECT	71	73

Abbreviations: hypo, hypoperfusion; Rx, treatment.
*$P = .037$ Fisher Exact test.
†$P < .001$ Fisher Exact test.

Discussion

In this study, balloon angioplasty was compared with papaverine infusion as treatment for cerebral vasospasm after subarachnoid hemorrhage in 44 patients. Balloon angioplasty of the proximal intracranial arteries improved brain perfusion in 70% by SPECT and improved velocities in 93% by TCD. Intraarterial papaverine improved brain perfusion in 42% by SPECT and velocities in 43% by TCD. Time delay of 12 hours between intervention and these studies may have affected the results. The effect of papaverine may be sustained only in some patients.

SPECT and TCD most often were in agreement (in 71% of cases or more) regarding improvement versus no improvement as ascertained by both methods. Previous work has shown that SPECT and TCD have a high rate of

agreement in the evaluation of vasospasm.[10,11] In most of the disagreements between TCD and SPECT in this study, TCD showed improved velocities in the setting of no change or worsened perfusion on SPECT. This finding relates either to persistent distal vessel vasospasm, which is not monitored well by TCD,[12,13] or by prolonged ischemia that has caused permanent tissue injury, even though the vessel may have responded well to the mechanical or pharmacologic dilatation and maintained patency.

Other techniques are available for monitoring of cerebral hemodynamics after subarachnoid hemorrhage, including xenon CT and positron emission tomography.[14,15] However, the wide availability of SPECT and TCD imaging equipment makes these technologies much more accessable in most centers. The single drawback to Tc-99m HMPAO SPECT is that it does not yield absolute blood flow values that xenon CT or Xe-133 SPECT can generate.[14,16] Nevertheless, with the use of baseline SPECT imaging after surgery for aneurysm clipping, the subsequent SPECT images and changes in cerebral blood flow that may accompany them are well used for important patient management decisions at our center.[11,12] Also, the Tc-99m radiopharmaceutical injection is without side effects and the scan can be performed at any time without need for immediate scanning as would be the case with xenon CT or Xe-133 SPECT. SPECT is also safer and less prone to artifacts than diffusion/perfusion magnetic resonance imaging for intubated and mechanically ventilated patients on life support with intracranial pressure monitors in place and/or with ventriculostomies. There are no contraindications to internal metal objects including pacemakers or other internal or external devices with use of SPECT.[17,18]

Although, this and other studies,[19] have demonstrated that balloon angioplasty is the favored technique for improving blood flow in delayed ischemia due to cerebral vasospasm that is refractory to medical treatment, there is still a role for papaverine in treating distal vessel vasospasm (which is unapproachable by balloon catheter) as well as providing improved access of the vessel for the microballoon catheter. Based on previous experience, TCD velocities decrease after successful balloon angioplasty of proximal vessels. We have previously evaluated the ratios of the intracranial to extracranial internal carotid artery velocities before and after intervention, which takes into account flow changes.[19] These ratios are lower after balloon angioplasty, indicating that vessel dilatation has a more pronounced effect on velocities than the moderate increase in flow that it produces. We have occasionally observed persistent high velocities in distal vessels not treated adequately by proximal vascular dilatation. This work has shown that SPECT and TCD are complementary in the evaluation of vasospasm and in the assessment of interventional therapy. The combination of these techniques provides a noninvasive and safe approach to the monitoring of the complex and changing nature of cerebral hemodynamics after subarachnoid hemorrhage, before and after treatment for cerebral vasospasm.

References

1. Zubkov YN, Nikiforov BM, Shustin VA. Balloon catheter technique for the dilatation of constricted cerebral arteries after aneurysmal subarachnoid hemorrhage. Acta Neurochir (Wien) 1984;70:65-79.
2. Eskridge JM, Newell DW, Pendleton GA. Transluminal angioplasty for treatment of vasospasm. Neurosurg Clin N Am 1990;1:387-399.
3. Kassell NF, Helm G, Simmons N, et al. Treatment of cerebral vasospasm with intra-arterial papaverine. J Neurosurg 1992;77:848-852.
4. Lewis DH, Eskridge JM, Newell DW, et al. Brain SPECT and the effect of cerebral angioplasty in delayed ischemia due to vasospasm. J Nucl Med 1992;33:1789-1796.
5. Lewis DH, Eskridge JM, McAuliffe W, et al. Effect of intra-arterial papaverine on cerebral blood flow in vasospasm after subarachnoid hemorrhage: a study using single-photon emission computed tomography. J Stroke Cerebrovasc Dis 1995;5:24-28.
6. Awad IA, Carter LP, Spetzler RF, et al. Clinical vasospasm after subarachnoid hemorrhage: Response to hypervolemic hemodilution and arterial hypertension. Stroke 1987;18:365-372.
7. Solomon RA, Fink ME, Lennihan L. Prophylactic volume expansion therapy for the prevention of delayed cerebral ischemia after early aneurysm surgery: Results of a preliminary trial. Arch Neurol 1988;45:325-332.
8. McAuliffe W, Townsend M, Eskridge JM, et al. Intracranial pressure changes induced during papaverine infusion for treatment of vasospasm. J Neurosurg 1995;83:430-434.
9. Chang L-T. A method for attenuation correction in radionuclide computed tomography. IEEE Trans Nucl Sci 1978;NS-25:638-643.
10. Davis SM, Andrews JT, Lichtenstein M, et al. Correlations between cerebral arterial velocities, blood flow, and delayed ischemia after subarachnoid hemorrhage. Stroke 1992;23:492-497.
11. Lewis DH, Hsu S, Eskridge J, et al. Brain SPECT and transcranial Doppler ultrasound in vasospasm-induced delayed cerebral ischemia after subarachnoid hemorrhage. J Stroke Cerebrovasc Dis 1992;2:12-21.
12. Lewis DH, Newell DW, Winn HR. Delayed ischemia due to cerebral vasospasm occult to transcranial Doppler: An important role for cerebral perfusion. SPECT. Clin Nucl Med 1997;22:238-240.
13. Newell DW, Grady MS, Eskridge JM, et al. Distribution of angiographic vasospasm after subarachnoid hemorrhage: Implications for diagnosis by transcranial Doppler ultrasonography. Neurosurgery 1990;27:574-577.
14. Firlik AD, Kaufmann AM, Jungreis CA, et al. Effect of transluminal angioplasty on cerebral blood flow in the management of symptomatic vasospasm following aneurysmal subarachnoid hemorrhage. J Neurosurg 1997;86:830-839.
15. Powers WJ, Grubb RL, Jr, Baker RP, et al. Regional cerebral blood flow and metabolism in reversible ischemia due to vasospasm. Determination by positron emission tomography. J Neurosurg 1985;62:539-546.

16. Deutsch G, Mountz JM, Liu HG, et al. Xenon-133 brain SPECT provides improved sensitivity to cerebrovascular stress studies. J Nucl Med 1997;5:37P (abstr, suppl).

17. Boutin RD, Briggs JE, Williamson MR. Injuries associated with MR imaging: Survey of safety records and methods used to screen patients for metallic foreign bodies before imaging. AJR 1994;162:189-194.

18. Culebras A, Kase CS, Masdeu JC, et al. Practice guidelines for the use of imaging in transient ischemic attacks and acute stroke: A report of the Stroke Council, AHA. Stroke 1997;28:1480-1497.

19. Elliott JP, Newell DW, Lam DJ, et al. Comparison of balloon angioplasty and papaverine infusion for the treatment of vasospasm following aneurysmal subarachnoid hemorrhage. J Neurosurg 1998;2:277-284.